



University of Illinois

EYE and EAR INFIRMARY

Ophthalmology & Visual Sciences

Pediatric Ophthalmology

Grand Rounds

12-08-10

Introduction: Ben Ticho, MD (*Attending*)

This week's Pediatric Ophthalmology Grand Rounds presents several interesting cases encountered by our faculty.

Edited by Clement Chow, MD and Javaneh Abbasian, MD. Photos by Mark Janowicz (unless otherwise noted). All photos are property of UIC.
© Copyright 2010 by the Department of Ophthalmology, University of Illinois College of Medicine. All rights reserved.



Hermansky-Pudlak Syndrome: Elizabeth Grace, MD (*Resident*)



A 4 mo Hispanic boy was sent for nystagmus evaluation. The child was an otherwise healthy boy, with horizontal pendular nystagmus noted around 1 month of age. The child had iris transillumination defects on slit lamp exam, mild hyperopic astigmatism, and a blond fundus with foveal hypoplasia on dilated fundus exam. Initially, the boy was thought to have ocular albinism and was sent to genetics clinic. At the follow up, one year later, he had a new onset head-bobbing, an MRI came back as normal, with no mass or hydrocephalus. Two years later, he was noted to have easy bruising and epistaxis often, thus he was referred back to genetics clinic who recommended testing for Hermansky-Pudlak Syndrome.

His genetic tests came back positive for Hermansky-Pudlak Syndrome, with a homozygous 3.9kb deletion in HPS3 gene. His most recent exam in Nov 2010, the now 12 year-old has a corrected visual acuity of 20/70, 20/80 at distance, 20/30 at near, horizontal pendular nystagmus, resolved head-bobbing, and foveal hypoplasia OU.

Diagnosis: Hermansky-Pudlak Syndrome

BACKGROUND Albinism is a heritable condition, thus the pediatric ophthalmologist plays an important role in detecting albinism and referring the patient on for genetic testing and counseling. Hermansky-Pudlak Syndrome (HPS) is particularly interesting form of tyrosinase-positive oculocutaneous albinism. The patients have a variety of skin/hair, ocular, systemic findings including: hypopigmented skin/hair, reduced iris pigment, iris transillumination defects, reduced retinal pigment, foveal hypoplasia, nystagmus, bleeding diathesis including easy bruising, epistaxis, prolonged bleeding after tooth extraction/surgery, pulmonary fibrosis, granulomatous colitis.

Testing for HPS includes genetic testing for mutations in genes: HPS1, AP3B1, HPS3, HPS4, HPS5, HPS6, DTNBP1, BLOC1S3. On electron microscopy of platelets these patients have an absence of platelet dense bodies. Normally, dense bodies are involved in the secondary aggregation response of platelets, thus platelets without dense bodies are unable to attract other platelets for this secondary reaction.

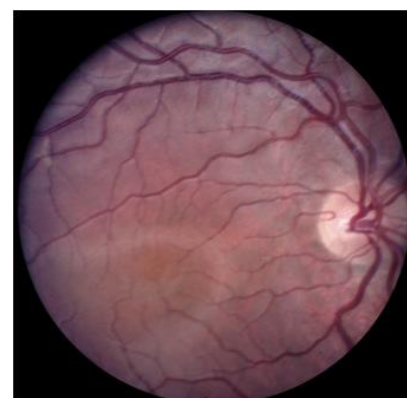


FIGURE 1

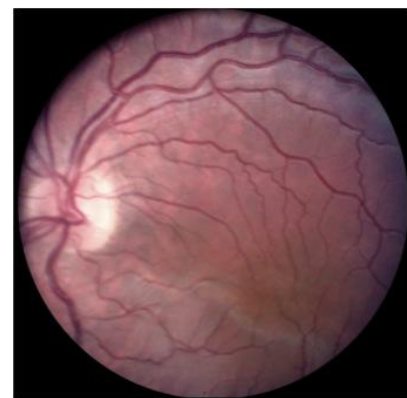

FIGURE 2

Hermansky-Pudlak Syndrome (continued)

Interestingly, HPS is very common in Puerto Rico with approximately 1 in 1800 Puerto Ricans affected. For our patient, the HPS3 gene mutation is a milder form of HPS, unlike HPS1 gene mutation which can have the often fatal manifestation of pulmonary fibrosis. Patients with HPS have many needs including: genetic counseling, refractive errors treated, low vision aids as needed, skin protection from the sun, avoidance of smoke/smoking, safety precautions with sports, avoiding aspirin/NSAIDs, up to date influenza and pneumococcal vaccines, and to notify all their surgeons/dentists of their condition and possible need for platelet coverage after surgery.

References:

1. Pediatric Ophthalmology BCSC Section 6. 2009-2010, pages 345-348, 159-171.
2. Gahl WA. Hermansky-Pudlak Syndrome. GeneReviews. University of Washington, Seattle; 1993. <http://www.ncbi.nlm.nih.gov/books/NBK1287/>
3. Summers CG. Albinism: Classification, Clinical Characteristics, and Recent Findings. *Optom Vis Sci* 2009;86:659-662.
4. Gronskov K, Ek J, Brondum-Nielsen K. Oculocutaneous albinism. *Orphanet Journal of Rare Diseases* 2007;2:43.

Marcus Gunn Jaw Winking Synkinesis: Erica Oltra, MD (Resident)



J.S. is a 5 ½ year old African American male who presented with left upper lid ptosis since birth. His parents state his ptosis changes with the position of his jaw. He has a past medical history of prematurity and asthma. His exam was significant for chin elevation and a right head tilt. He had a decreased palpebral fissure and MRD1 measurements of 4-9mm and -2mm, respectively. He had no levator function.

He also had an intermittent esotropia and intermittent hyperopia with jaw opening. The diagnosis was made clinically as Marcus Gunn Jaw Winking Synkinesis (MGJWS).

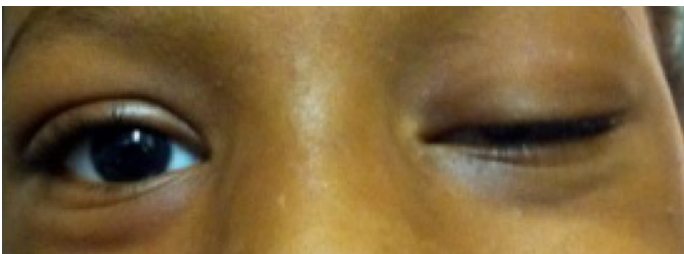


FIGURE 3
External Exam in primary gaze.

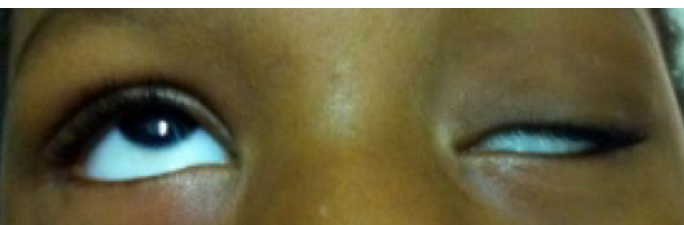


FIGURE 4
External Exam in up-gaze.

BACKGROUND MGJWS is a pterygoid-levator synkinesis where the nerve fibers of CNV get misdirected to CNVII, which controls the levator. This causes a “wink” with movement of the jaw to the contralateral side. It is thought to account for 5% of all congenital blepharoptosis. It is important to inquire about changes in ptosis when feeding. Many patients may learn to hold their jaw in an altered position in order to relieve some degree of ptosis and allow them binocularity.

Commonly associated eye conditions include horizontal and vertical strabismus, amblyopia and double elevator palsy. Patients are generally observed and surgical treatment is reserved for patients with concern for amblyopia or for cosmesis. If there is a mild wink with severe ptosis, unilateral levator advancement is performed. However, if there is a moderate to severe wink, the levator must be disabled. The most common procedures performed are unilateral levator disabling with unilateral versus bilateral frontalis sling, taken from autogenous fascia lata.

Both the bilateral and unilateral frontalis slings provide symmetric upper eyelid height in primary gaze, however there is a statistically significant difference in the asymmetry in upper lid height in down-gaze. The unilateral frontalis sling is only an option for patients without amblyopia since patients must rely on their frontalis muscle to correct for the unilateral ptosis. While the bilateral frontalis sling may offer a better cosmetic result, parents are often hesitant to operate on the unaffected side.

Our patient J.S. was referred to oculoplastic surgery, however no decisions have yet been made about his treatment plan.

References:

1. Bowyer J.D., Sullivan T.J., Management of Marcus Gunn Jaw Winking Synkinesis. *Ophth Plast Recon Surg.* 2004. 20(2): 92-8.
2. Demirci H. et.al., Marcus Gunn jaw-winking synkinesis: clinical features and management. *Ophthalmology.* 2010. 117(7): 1447-52.
3. Park DH., et.al., Treatment of the jaw-winking syndrome. *Ann Plast Surg.* 2008. 60(4): 404-9.
4. <http://webeye.ophth.uiowa.edu>

Traumatic Hyphema: Josh Hou, MD (*Resident*)



Patient MC is an otherwise healthy 10yo AAM who initially presented to an OSH after suffering a sling-shot directly to the right eye. A CT scan was obtained at the OSH and showed no orbital fracture or globe rupture. He was then transferred to UIC for further management.

On initial exam, the patient was noted to have reduced visual acuity OD to 20/200 (ph NI). At the slit lamp, he was further noted to have a small central 0.5x0.5mm epithelial defect, a 1.5mm layer hyphema, and a traumatic cataract with rupture of the anterior lens capsule. At the time the lens

cortex was intact with no evidence of lenticular prolapse (fig. 5). Posterior exam was limited OD and a B-scan was performed which showed no evidence of retinal detachment, vitritis, or vitreous hemorrhage. Similar examination OS was unremarkable. A sickle cell prep was obtained and returned negative for disease or trait.

Due to the presence of a traumatic hyphema and the stable appearance of the lens, the decision was made to delay cataract extraction. The patient was thus started on medical therapy for management of the traumatic hyphema and epithelial defect. On therapy, the patient's epithelial defect rapidly resolved. However he soon developed microcystic edema with elevated IOP (Tmax 34) requiring escalation of his IOP lowering drops. With maximized topical therapy the IOP was eventually controlled. The patient's hyphema subsequently resolved and pressure resolved off drops. At that time, progressive hydration of the lens with subsequent prolapse of lens material was noted on exam (fig. 6) and patient was then taken for cataract extraction.

Intraoperatively, Trypan blue was used to delineate the lens capsule and the anterior nasal capsule was noted to be completely absent. However, after removal of the traumatic cataract an intact posterior capsule was identified. Due to concerns regarding the integrity of the lens capsule, the decision was made to defer IOL placement. After 1 month, patient underwent secondary sulcus IOL placement. His post-operative visual acuity of 20/25 OD.

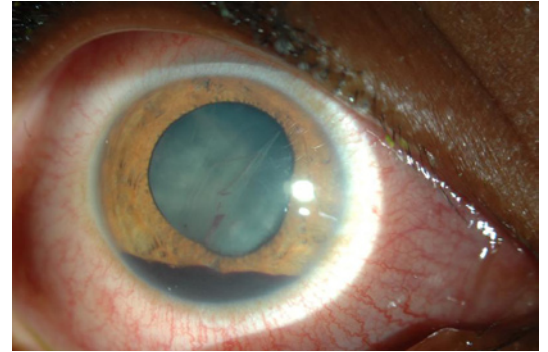


FIGURE 5

Slit lamp photo OD (2days after initial trauma) showing evidence of a traumatic hyphema, traumatic cataract, and anterior capsular tear.

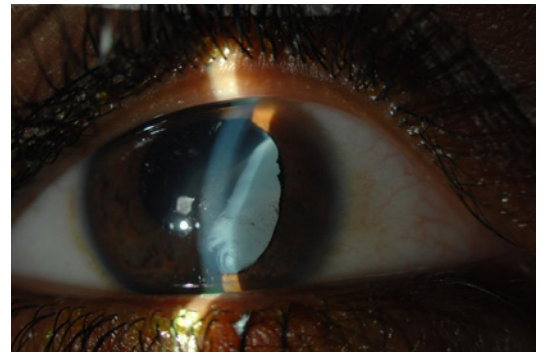


FIGURE 6

Slit lamp photo OD (2wks after initial trauma) showing lens hydration and prolapse of lens material.

BACKGROUND Management of pediatric traumatic cataract is notably more complex than similar cases in adults. Significant controversy exists regard the ideal approach (IOL vs. aphakia) and timing of therapy (primary vs. secondary). In children under the age of 2, IOL placement is particularly controversial due to the unique risks for poor outcomes in this patient population, including: changing axial length and corneal diameter, decreased scleral rigidity and smaller ocular size, and finally a longer post-op life span. In recent years, the literature has suggested that in children over the age of 2, IOL placement after cataract extraction may yield improved long-term outcomes. A study published in the *Am J Ophthalmol* in 1997 (BenEzra et al., 1997) found that in a cohort of kids age 2 to 13 who underwent cataract extraction for traumatic cataracts, 73.9% of kids who also underwent IOL placement (primary or secondary) achieved a BCVA of at least 20/50, while only 35.3% of kids left aphakic and fitted with CTL achieved a similar level of BCVA.

Additional controversy regarding timing of surgery also exists. In management of pediatric traumatic cataracts, cataract extraction can be performed at the time of trauma (primary) or as a delayed procedure (secondary). IOL placement can also be done at the time of surgery (primary) or delayed (secondary) as well. A recent study in *Graefes Arch Clin Exp Ophthalmol* looking at timing of traumatic cataract surgery (pediatric and adult) found no significant difference in outcomes regardless of whether the procedure or IOL placement was performed primary or secondary (Rumelt et al., 2010).

References:

1. Churchill AJ, Noble BA, Etchells DE, George NJ, Factors affecting visual outcome in children following unioocular traumatic cataract. *Eye* 1995; 9:285-291.
2. Brady KM, Atkinson CS, Kilty LA, Hiles DA. Cataract surgery and intraocular lens implantation in children. *Am J Ophthalmol.* 1995; 120:1-9.
3. Benezra D, Cohen E, Rose L. Traumatic cataract in children: correction of aphakia by contact lens or intraocular lens. *Am J Ophthalmol.* 1997; 123:773-782.
4. Chuang LH, Lai CC. Secondary intraocular lens implantation of traumatic cataract in open-globe injury. *Can J Ophthalmol.* 2005 Aug; 40(4):454-9.
5. Agarwal A, Kumar DA, Nair V. Cataract surgery in the setting of trauma. *Curr Opin Ophthalmol.* 2010 Jan; 21(1):65-70.
6. Rumelt S, Rehany U. The influence of surgery and intraocular lens implantation timing on visual outcome in traumatic cataract. *Graefes Arch Clin Exp Ophthalmol.* 2010 Sep;248(9):1221-3.

Upcoming Grand Rounds

Illinois Eye and Ear Infirmary Ophthalmology Grand Rounds are held Wednesdays at 5:00 pm on the UIC campus at 909 S. Wolcott in the College of Medicine Research Building. For a complete schedule go to www.uic.edu/com/eye and click on Grand Rounds under the Education drop down menu. Or, call 312-996-6590.

UPCOMING CME COURSES

March 19-25, 2011	4th Annual Illinois Eye Review
April 15, 2011	4th Annual Retina Symposium
April 22-23, 2011	UIC Cornea Symposium
May 11, 2011	Glaucoma Symposium
June 24, 2011	35th Annual Alumni Resident Day: Advances in the Management of Serious Eye Disease