

Blood Can Be Very Bad: CT Interpretation Course Guide

Andrew D. Perron, MD, FACEP

EM Residency Program Director
Department of Emergency Medicine
Maine Medical Center
Portland, ME

- I. Course Description:** Recently published data indicates a concerning rate of head CT misinterpretations by emergency physicians. This session will help emergency physicians improve their ability to interpret such studies. The physics of CT scanning will be reviewed. A review of normal neuroanatomy and CT appearance, followed by a detailed review of neuropathologic conditions frequently encountered in the ED will follow. The diagnoses covered will include traumatic injuries, such as epidural and subdural hematoma, skull fracture, and contusion, and non-traumatic conditions such as stroke, subarachnoid hemorrhage, and hydrocephalus. Methods to avoid errors of interpretation will be discussed.
- II. Course Objectives:** Upon completion of this course, participants will be able to:
1. Discuss the physics that apply to CT scanning, including Hounsfield numbers, windows, and frequent sources of scan artifact such as volume averaging.
 2. Describe the CT appearance of normal brain anatomy.
 3. Be able to identify the pathologic conditions found on cranial CT commonly encountered in the Emergency Department.
 4. Identify pathologic conditions frequently misinterpreted by emergency physicians, and techniques to help avoid such errors.

- III. Introduction:** The cranial computed tomograph (CT) has assumed a critical role in the practice of emergency medicine for the evaluation of intracranial emergencies, both traumatic and atraumatic. A number of published studies have revealed a deficiency in the ability of emergency physicians to interpret head CTs. Nonetheless, in many situations the emergency physician must interpret and act upon head CTs initially without assistance from other specialists. Despite the immediate importance for emergency physicians to recognize intracranial emergencies on head CT, few receive formalized training in this area during medical school or residency.

History of CT: In 1970, Sir Jeffrey Hounsfield combined a mathematical reconstruction formula with a rotating apparatus that could both produce and detect x-rays, producing a prototype for the modern-day CT scanner. For this work he received both a Nobel Prize and a knighthood.

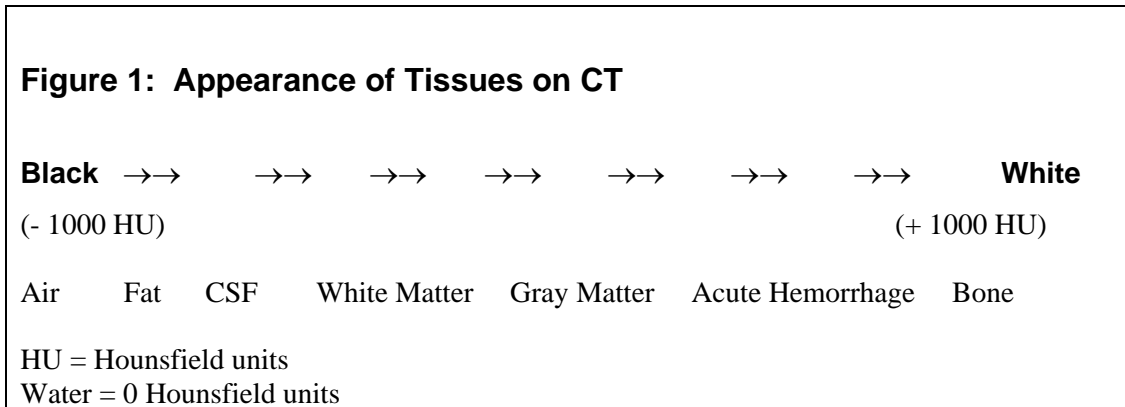
- IV. X-Ray Physics:** The most fundamental principle behind radiography of any kind is the following statement: **X-rays are absorbed to different degrees by different tissues.** Dense tissues, such as bone, absorb the most x-rays, and hence allow the fewest through the body part being studied to the film or detector opposite. Conversely, tissues with low density (air/fat), absorb almost none of the x-rays, allowing most to pass through to a film or detector opposite.

Conventional radiographs: Conventional radiographs are two-dimensional images of three-dimensional structures, as they rely on a summation of tissue densities penetrated by x-rays as they pass through the body. Denser objects, because they tend to absorb more x-rays, can obscure or attenuate less dense objects. Also subject to x-ray beam scatter, which further blurs or obscures low-density objects.

Computed tomography: As opposed to conventional x-rays, with CT scanning an x-ray source and detector, situated 180° across from each other, move 360° around the patient, continuously sending and detecting information on the attenuation of x-rays as they pass through the body. Very thin x-ray beams are utilized, which minimizes the degree of scatter or blurring. Finally, a computer manipulates and integrates the acquired data and assigns numerical values based on the subtle differences in x-ray attenuation. Based on these values, a gray-scale axial image is generated that can distinguish between objects with even small differences in density.

Pixels: (Picture element) Each scan slice is composed of a large number of pixels which represent the scanned volume of tissue. The pixel is the scanned area on the x and y axis of a given thickness.

Attenuation coefficient: The tissue contained within each pixel absorbs a certain proportion of the x-rays that pass through it (e.g. bone absorbs a lot, air almost none). This ability to block x-rays as they pass through a substance is known as “attenuation”. For a given body tissue, the amount of attenuation is relatively constant, and is known as that tissue’s “attenuation coefficient”. In CT scanning, these attenuation coefficients are mapped to an arbitrary scale between –1000 (air) and +1000 (bone). (See Figure 1 below)



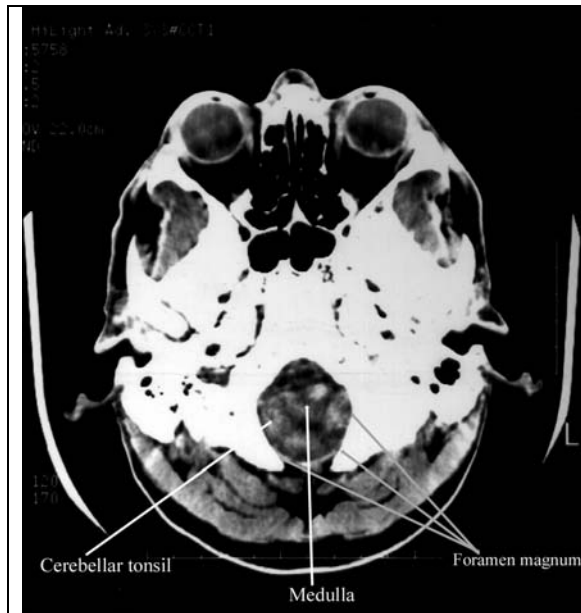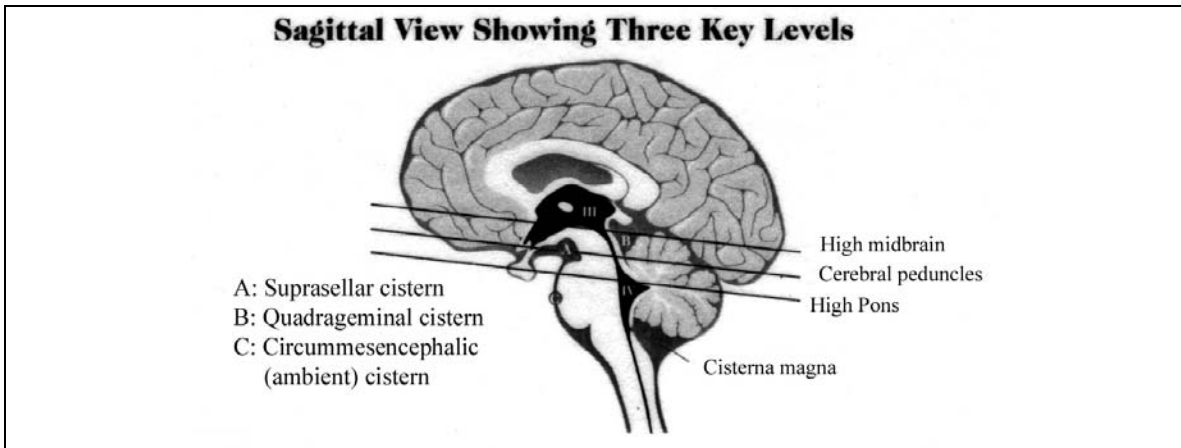
This scale -1000 to +1000 is the Hounsfield scale in honor of Sir Jeffrey Hounsfield. The Hounsfield numbers define the characteristics of the tissue contained within each pixel, and are represented by an assigned portion of the gray-scale.

Windowing: Windowing allows the CT reader to focus on certain tissues on a CT scan that fall within set parameters. Tissues of interest can be assigned the full range of blacks and whites, rather than a narrow portion of the gray-scale. With this technique, subtle differences in tissue densities can be maximized.

V. Normal Neuroanatomy as seen on Head CT:

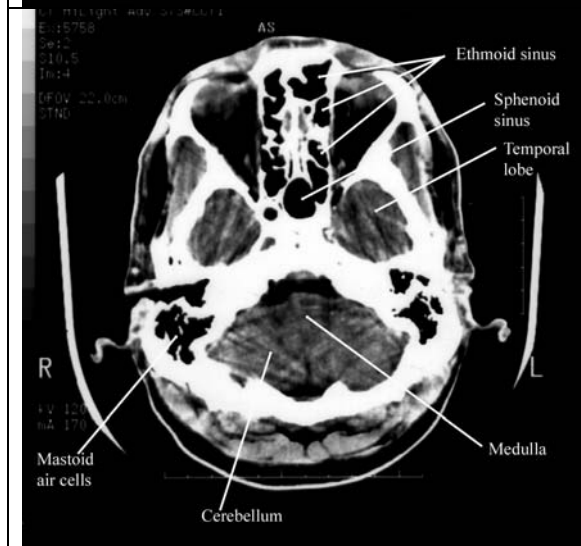
As with x-ray interpretation of any body part, a working knowledge of normal anatomic structures and location is fundamental to the clinician's ability to detect pathologic variants. Cranial CT interpretation is no exception. Paramount in head CT interpretation is familiarity with the various structures (from parenchymal areas such as basal ganglia) to vasculature, cisterns and ventricles. Finally knowing neurologic functional regions of the brain help when correlating CT with physical examination findings.

While a detailed knowledge of cranial neuroanatomy and its CT appearance is clearly in the realm of the neuroradiologist, familiarity with a relatively few structures, regions, and expected findings will allow for sufficient interpretation of most head CT scans by the emergency physician.



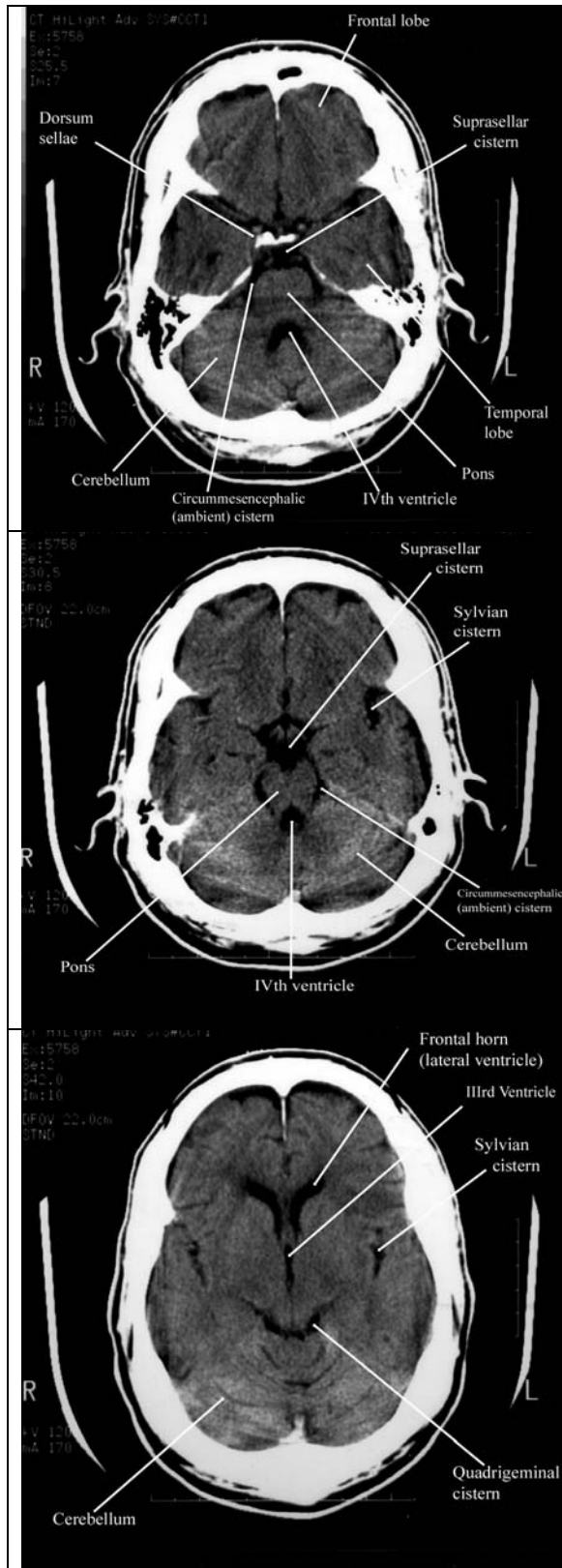
Posterior Fossa:

- Cerebellum
- Medulla/Pons
- Sinuses
- Basilar artery
- Skull Base
 - Foramen Magnum
 - Clinoids
 - Petrosal bone
 - Sphenoid bone
 - Sella Turcica
 - Mastoid air cells
 - Orbits



Posterior Fossa:

- Cerebellum
- Medulla/Pons
- Sinuses
- Basilar artery
- Skull Base
 - Foramen Magnum
 - Clinoids
 - Petrosal bone
 - Sphenoid bone
 - Sella Turcica
 - Mastoid air cells
 - Orbits



High Pons (1st Key Level)

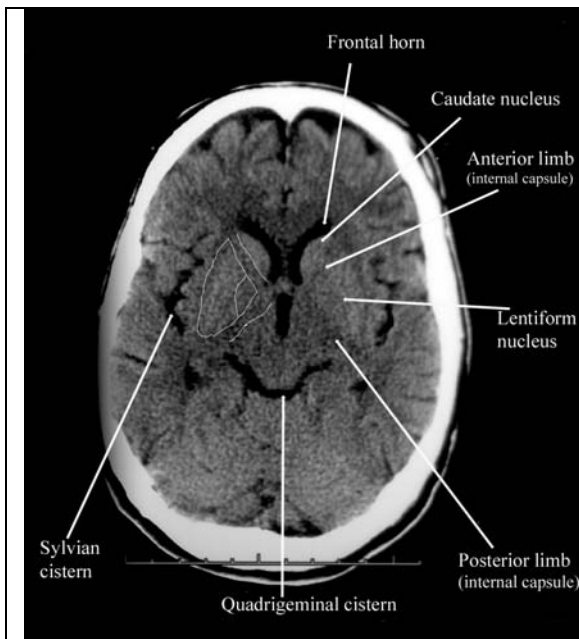
- Pons
- IVth Ventricle
- Circummesencephalic cistern
- Temporal lobes
- Frontal lobes
- Cerebellum
- Basilar artery
- Low suprasellar cistern

Cerebral Peduncles (2nd Key Level)

- Circle of Willis
- Suprasellar Cistern
- Circummesencephalic cistern
- Clinoids (+/-)
- Sylvian cistern
- Temporal fossa
- IVth Ventricle

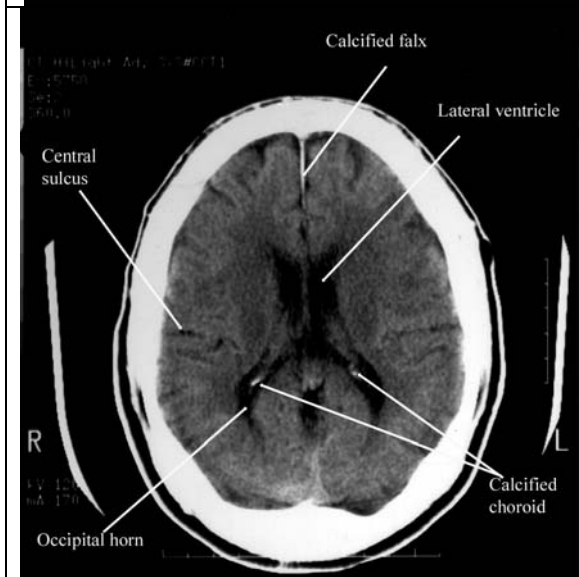
High Midbrain Level (3rd Key Level)

- Lateral ventricles
- IIIrd Ventricle
- Basal ganglia
- Sylvian cistern
- Quadrigeminal cistern



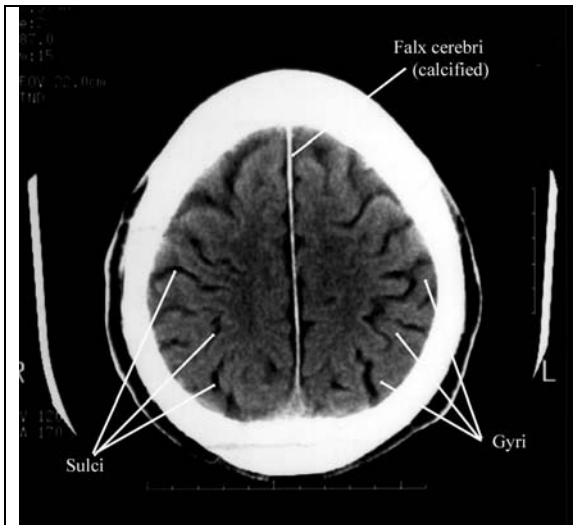
Basal Ganglia Region

- Lenticular nuclei
 - Globus pallidus
 - Putamen
- Internal capsule
 - Anterior limb
 - Posterior limb
- Caudate
Insular ribbon



Upper Cortex

- Gray-white differentiation
- Lateral ventricles
- Calcified choroid/pineal
- Cortical gyral/sulcal pattern



Upper Cortex

- Gray-white differentiation
- Lateral ventricles
- Calcified choroid/pineal
- Cortical gyral/sulcal pattern

CSF Flow:

Lateral ventricles (Choroid plexus) → IIIrd Ventricle → Aqueduct of Sylvius → IVth Ventricle → Magendie and Lushka → Subarachnoid space.

- 0.5-1cc/minute in adults.
- Adult CSF Volume = 150cc

Adult CSF Production 500-700 cc/day (i.e. CSF “turns over” 3-5 times/day)

VI. Neuropathology

Building on the first portion of the course, we will look at the most common traumatic and a-traumatic pathological processes that are found on emergent cranial CT scans. Utilizing a systematic approach is one way that the clinician can ensure that significant neuropathology will not be missed. Just as physicians are taught a uniform, consistent approach to reading an ECG (rate, rhythm, axis, etc.), the cranial CT can also be broken down into discreet entities, attention to which will help avoid the pitfall of a missed diagnosis.

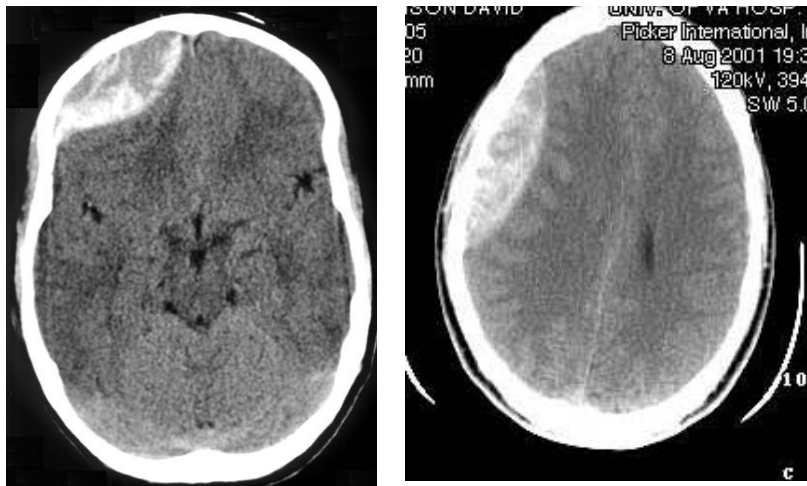
One suggested mechanism to employ in avoiding a missed diagnosis is using the mnemonic “**Blood Can Be Very Bad**”. In this mnemonic, the first letter of each word prompts the clinician to search a certain portion of the cranial CT for pathology: **B**lood = blood, **C**an = cisterns, **B**e = brain, **V**ery = ventricles, **B**ad = bone.

Use the entire mnemonic when examining a cranial CT scan, as the presence of one pathological state does not rule out the presence of another one.

Blood- Acute hemorrhage will appear hyperdense (bright white) on cranial CT. This is attributed to the fact that the globin molecule is relatively dense, and hence effectively absorbs x-ray beams. Acute blood is typically in the range of 50-100 Hounsfield units.

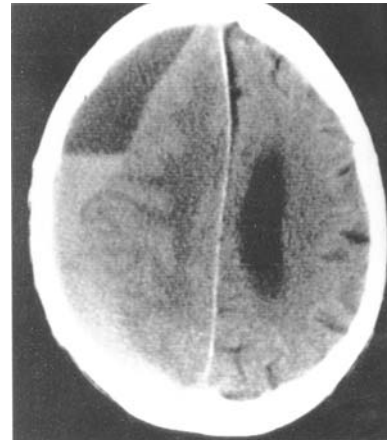
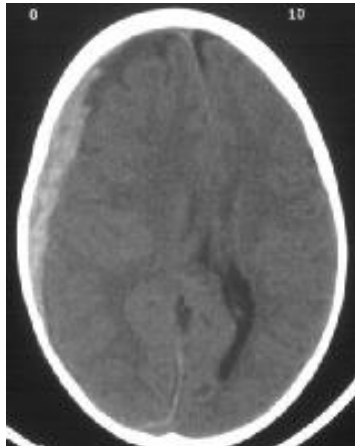
As the blood becomes older and the globin molecule breaks down, it will lose this hyperdense appearance, beginning at the periphery and working centrally. On CT blood will 1st become isodense with the brain (4 days to 2 weeks, depending on clot size), and finally darker than brain (>2-3 weeks). The precise localization of the blood is as important as identifying its presence.

- 1. Epidural hematoma (EDH)**-Most frequently, a lens shaped (biconvex) collection of blood, usually over the brain convexity. EDH never crosses a suture line. Primarily (85%) from arterial laceration due to a direct blow, with middle meningeal artery the most common source. A small proportion can be venous in origin. With early surgical therapy, mortality of <20% can be expected.



- 2. Subdural hematoma (SDH)**- Sickle or crescent shaped collection of blood, usually over the convexity. Can also be interhemispheric or along the tentorium. SDH will cross suture lines. Subdural hematoma can be either an acute lesion, or a chronic one. While both are primarily from venous disruption of surface and/or bridging vessels, the magnitude of impact damage is usually much higher in acute SDH. Acute SDH is frequently accompanied by severe brain injury, contributing to its poor prognosis. With acute SDH, overall significant morbidity and mortality can approach 60-80% primarily due to the tremendous impact forces involved (with the above mentioned damage to underlying parenchyma).

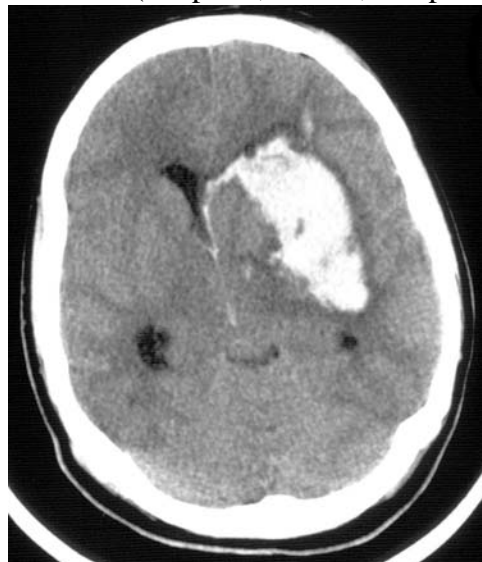
Chronic SDH, in distinction to acute SDH, usually follows a more benign course. Attributed to slow venous oozing after even a minor CHI, the clot can gradually accumulate, allowing the patient to compensate. As the clot is frequently encased in a fragile vascular membrane, these patients are at risk of re-bleeding with additional minor trauma. The CT appearance of a chronic SDH depends on the length of time since the bleed. Subdurals that are isodense with brain can be very difficult to detect on CT, and in these cases contrast may highlight the surrounding vascular membrane.



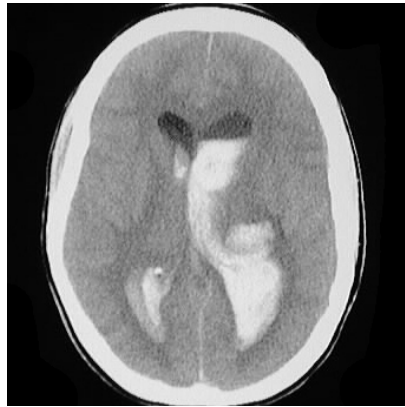- 3. Intraparenchymal hemorrhage** (aka Intracerebral hemorrhage ICH)—Cranial CT will reliably identify intracerebral hematomas as small as 5 mm. These appear as high-density areas on CT, usually with much less mass effect than their apparent size would dictate.

Nontraumatic lesions due to hypertensive disease are typically seen in elderly patients and occur most frequently in the basal ganglia region. Hemorrhage from such lesions may rupture into the ventricular space, with the additional finding of intraventricular hemorrhage on CT. Hemorrhage from amyloid angiopathy is frequently seen as a cortical based wedge-shaped bleed with the apex pointed medially. Posterior fossa bleeds (e.g. cerebellar) may dissect into the brainstem (pons, cerebellar peduncles) or rupture into the fourth ventricle.

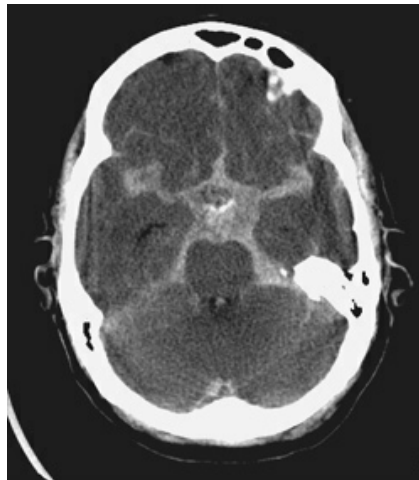
Traumatic intracerebral hemorrhages may be seen immediately following an injury. Contusions may enlarge and coalesce over first 2-4 days. Most commonly occur in areas where sudden deceleration of the head causes the brain to impact on bony prominences (temporal, frontal, occipital poles).



- 4. Intraventricular hemorrhage (IVH)-** can be traumatic, secondary to IPH with ventricular rupture, or from subarachnoid hemorrhage with ventricular rupture (especially PICA aneurysms). IVH is present in 10% of severe head trauma. Associated with poor outcome in trauma (may be marker as opposed to causative). Hydrocephalus may result regardless of etiology.



- 5. Subarachnoid hemorrhage (SAH)-** Hemorrhage into CSF space (cisterns, convexity). Hyperdensity is frequently visible within minutes of onset of hemorrhage. Most commonly aneurysmal (75-80%), but can occur with trauma, tumor, AVM (5%), and dural malformation. The etiology is unknown in approximately 15% of cases. Hydrocephalus complicates 20% of patients with SAH.



The ability of a CT scanner to demonstrate SAH depends on a number of factors, including generation of scanner, time since bleed, and skill of reader. Depending on which studies you read, the CT scan is 95-98% sensitive for SAH in the 1st 12 hours after the ictus. This sensitivity drops off as follows:

95-98% through 12 hours
90-95% at 24 hours
80% at 3 days
50% at 1 week
30% at 2 weeks

The location of the SAH on a CT scan has been used by some to prognosticate the location of the presumed aneurysm, although this has been challenged:

Anterior communicating artery aneurysm (30%): Blood in and around the interhemispheric fissure, suprasellar cistern, and brainstem.

Posterior communicating artery aneurysm (25%): Blood in suprasellar cistern.

Middle cerebral artery aneurysm (20%): Blood in the adjacent sylvian cistern and suprasellar cistern.

Aneurysmal SAH can also rupture into the intraventricular, intraparenchymal, and subdural spaces.

- 6. Extracranial** – often overlooked. Use extraaxial blood and soft-tissue swelling to lead you to subtle fractures in areas of maximal impact.

Cisterns- CSF collections jacketing the brain. 4 key cisterns must be examined for blood, asymmetry, and effacement (as with increased ICP).

Circummesencephalic – ring around the midbrain
Suprasellar- (Star-shaped) Location of the Circle of Willis
Quadrigeminal- W-shaped at top of midbrain
Sylvian- Between temporal and frontal lobes

Brain- Inhomogeneous appearance of normal gray and white matter. Examine for:
***Symmetry**- Easier if patient's head is straight in the scanner. Sulcal pattern (gyri) should be well differentiated in adults, and symmetric side-to-side.

***Grey-white differentiation**- Earliest sign of CVA will be loss of gray-white differentiation (the “insular ribbon” sign). Metastatic lesions often found at gray-white border.

***Shift**- Falx should be midline, with ventricles evenly spaced to the sides. Can also have rostral-caudal shift, evidenced by loss of cisternal space. Unilateral effacement of sulci signals increased pressure in one compartment. Bilateral effacement signals global increased pressure.

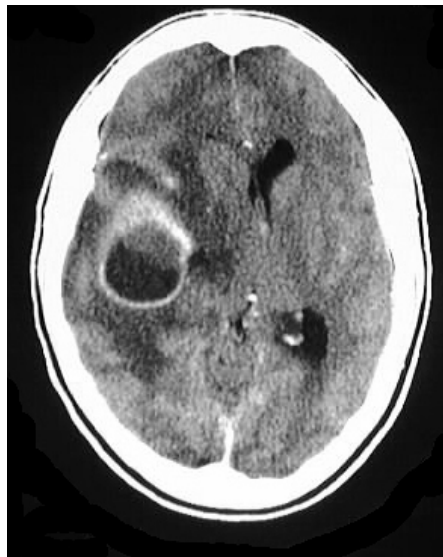
***Hyper/Hypodensity**- Increased density with blood, calcification, IV contrast. Decreased density with Air/gas (pneumocephalus), fat, ischemia (CVA), tumor.

Mass lesions:

Tumor: Brain tumors usually appear as hypodense, poorly-defined lesions on non-contrasted CT scans. From the radiology literature, it is estimated that 70-80% of brain tumors will be apparent without the use of contrast. Calcification and hemorrhage associated with a tumor can cause it to have a hyperdense appearance. Tumors should be suspected on a non-contrasted CT scan when significant edema is associated with an ill-defined mass. This vasogenic edema occurs because of a loss of integrity of the blood-brain barrier, allowing fluid to pass into the extracellular space. Edema, because of the increased water content, appears hypodense on the CT scan.

Intravenous contrast material can be used to help define brain tumors. Contrast media will leak through the incompetent blood-brain barrier into the extracellular space surrounding the mass lesion, resulting in a contrast-enhancing ring.

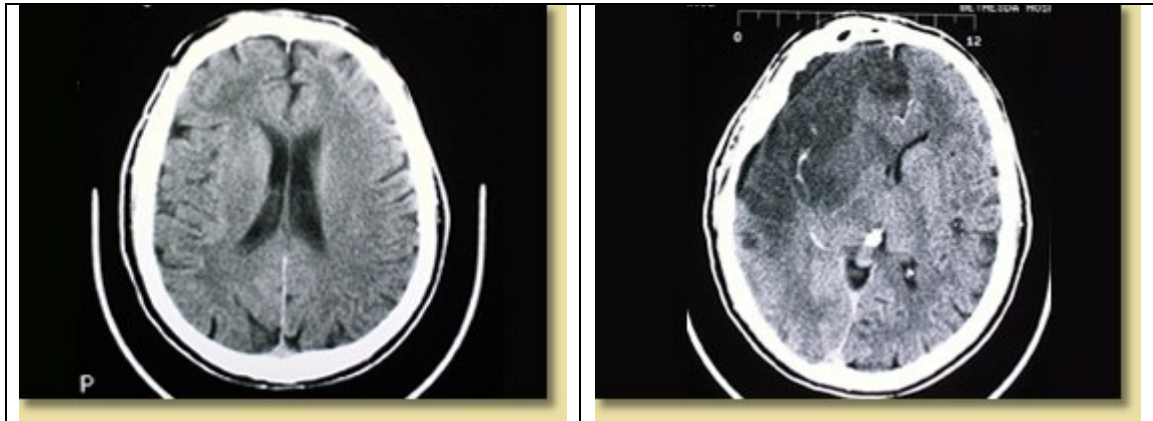
Once a tumor is identified, the clinician should make some determination of the following information: Location and size (intraaxial-within the brain parenchyma, or extraaxial), and the degree of edema and mass effect (e.g. is herniation impending due to swelling).



Abscess: Brain abscess will appear as an ill-defined hypodensity on non-contrast CT scan. A variable amount of edema is usually associated with such lesions and, like tumors, they frequently ring-enhance with the addition of intravenous contrast.

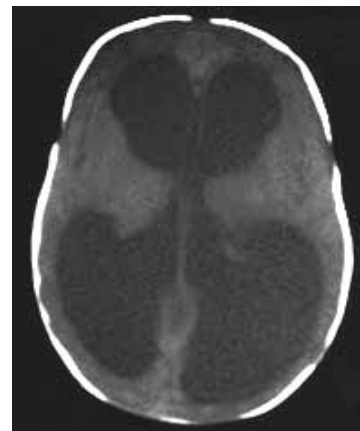
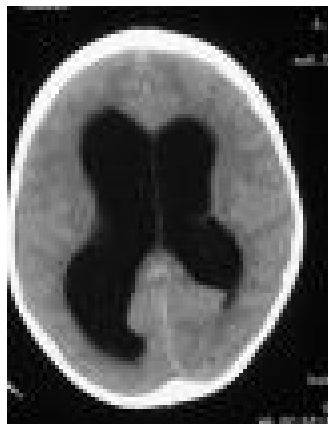Ischemic infarction:

Strokes are either hemorrhagic or non-hemorrhagic. Non-hemorrhagic infarctions can be seen as early as 2-3 hours following ictus (if you count ultra-early changes such as the “insular ribbon sign”), but most will not begin to be clearly evident on CT for 12-24 hours. The earliest change seen in areas of ischemia is loss of gray-white differentiation. This can initially be a subtle finding. Edema and mass effect are seen in association with approximately 70% of infarctions, and is usually maximal between days 3 and 5.



Lacunar infarctions are small, discrete non-hemorrhagic lesions, usually secondary to hypertension and found in the basal ganglia region.

Ventricles - Pathologic processes cause dilation (hydrocephalus) or compression/shift. Communicating vs. Non-communicating. Communicating hydrocephalus is first evident in dilation of the temporal horns (normally small, slit-like). The lateral, IIIrd, and IVth ventricles need to be examined for effacement, shift, and blood.

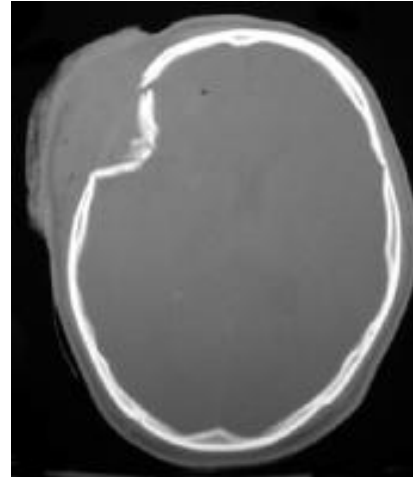
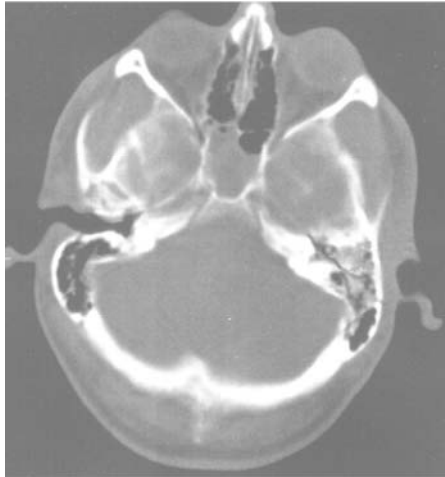

Bone - Has the highest density on CT scan (+1000 Hounsfield units). Note soft tissue swelling to indicate areas at risk for fracture.

Skull fracture:

Making the diagnosis of skull fracture can be confusing due to the presence of sutures in the skull. Fractures may occur at any portion of the bony skull. Divided into non-depressed (linear) or depressed fractures, the presence of any skull fracture should increase the index of suspicion for intracranial injury. The presence of intracranial air on a CT scan means that the skull and dura have been violated at some point.

Basilar skull fractures are most commonly found in the petrous ridge (look for blood in the mastoid air cells). Maxillary/ethmoid/sphenoid sinuses all should be visible and aerated: the presence of fluid in any of these sinuses in the setting of trauma should raise suspicion of a skull fracture.



Summary:

Cranial computed tomography is integral to the practice of emergency medicine, and is used on a daily basis to make important, time-critical decisions that directly impact the care of ED patients. An important tenet in the use of cranial CT is that accurate interpretation is required to make good clinical decisions. Cranial CT interpretation is a skill, like ECG interpretation, that can be learned through education, practice, and repetition.

Additional Readings:

Studies on Accuracy of ED CT Scan Interpretation:

Schreiger DL et al: Cranial computed tomography interpretation in acute stroke. *JAMA* 1998;279:1293-1297.

Perron AD et al: A multicenter study to improve emergency medicine residents' recognition of intracranial emergencies on computed tomography. *Ann Emerg Med* 1998;32:554-562.

Leavitt MA et al: Abbreviated educational session improves cranial computed tomography scan interpretations by emergency physicians. *Ann Emerg Med* 1997;30:616-621.

Alfaro DA et al: Accuracy of interpretation of cranial computed tomography in an emergency medicine residency program. *Ann Emerg Med* 1995;25:169-174.

Roszler MH et al: Resident interpretation of emergency computed tomographic scans. *Invest Radiol* 1991;26:374-376.

General Reference:

Cwinn AA et al: Emergency CT scans of the head: a practical atlas. Mosby Year Book, St. Louis, 1998.

Lee SH et al: Cranial MRI and CT, 4th ed. McGraw-Hill, New York, 1999.