Optimizing ED Management of Spinal Cord Injury:
A Diagnosis & Treatment Protocol

Scott Weingart, MD

Scott Weingart, MD

Assistant Professor
Director of ED Critical Care

Elmhurst Hospital Center
Mount Sinai School of Medicine
New York, NY

Scott Weingart, MD

Objectives

- Improve pt outcome in spinal injuries
- Know how to image trauma patients
- Improve treatment of spinal cord injuries
- Improve Emergency Medicine practice

Scott Weingart, MD

A Clinical Case

Scott Weingart, MD

SCI Procedure

Get them off of the Board

Scott Weingart, MD

SCI Procedure

Protect the Spine from Further Injury

Scott Weingart, MD

SCI Procedure

Properly Use Clinical Prediction Rules

Scott Weingart, MD

Nexus C-Spine Rule

- No midline tenderness
- No distracting injury
- No Neurodeficit
- No Alcohol or Drugs
- No Altered Mental Status
- No pain with neck movement

Ann Emerg Med. 1992 Dec;21(12):1454-60.

Scott Weingart, MD

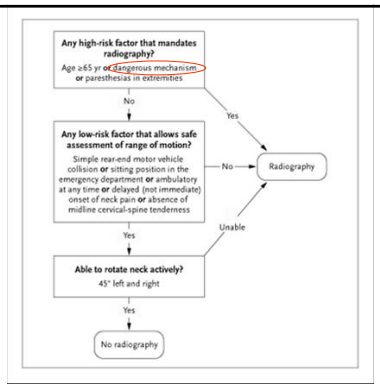

NEJM 2003;349:2510-8 and Ann Emerg Med 42:3:395-402.

SCI Procedure

Perform Appropriate Screening Studies

Scott Weingart, MD

Screening Studies

- Plain Films
- CT Scan
- Flexion-Extension
- MRI

Scott Weingart, MD

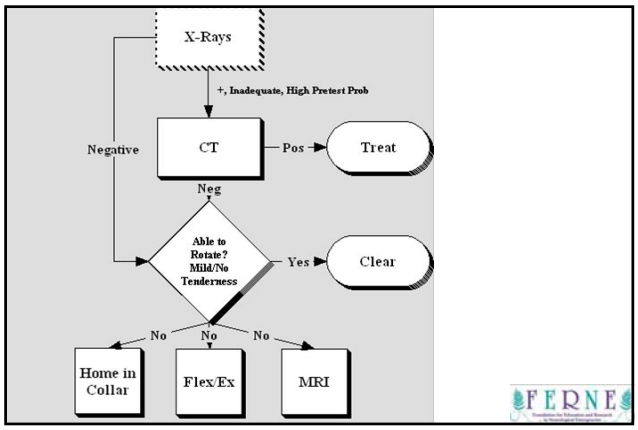

Confirmed Fracture

Scott Weingart, MD

SCI Procedure

Rule Out
Other Injuries

Scott Weingart, MD

SCI Procedure

Perform Appropriate
Follow-up Studies

Scott Weingart, MD

SCI Procedure

Stable or Unstable?

Scott Weingart, MD

Unstable Fractures

Jefferson Bit Off A Hangman's Thumb

Jefferson: C2 Burst Fx
Bifacet Dislocation or Fracture
Odontoid: II-body or III-Lateral masses
Any Fx with dislocation/subluxation
Hangman's: posterior C2 secondary to hyperextension
Teardrop: anterior chip of any vertebrae

Scott Weingart, MD

Confirmed Cord Injury

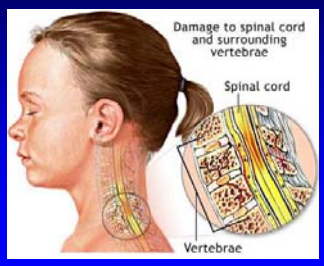

Scott Weingart, MD

SCI Procedure

Administer Steroids based
on Hospital Protocol

Scott Weingart, MD

Steroids

Solumedrol 30 mg/kg bolus
and then 5.4 mg/kg/hr for

23 additional hours if given within 3 hours of injury
or
47 hours if given between 3 and 8 hours

Scott Weingart, MD

SCI Procedure

Introduce the patient to a Neurosurgeon

Scott Weingart, MD

SCI Procedure

Perform a Detailed Spinal Cord Exam

Scott Weingart, MD

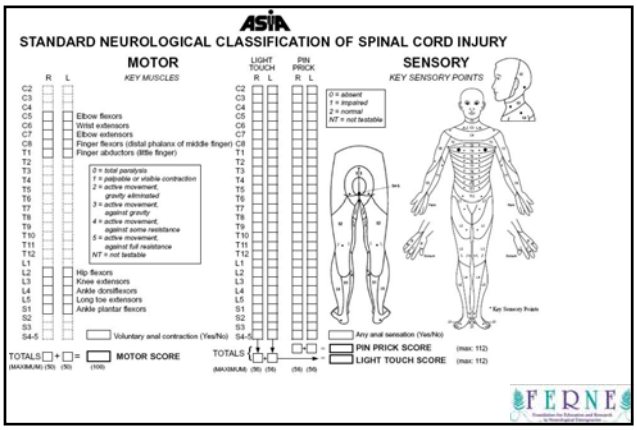

SCI Procedure

Determine their Level

Scott Weingart, MD

SCI Procedure

Determine Complete vs. Incomplete

Scott Weingart, MD

Important Parts of Testing

- Sacral Sensory Sparing
- Voluntary Anal Sphincter Contraction
- Sensation/Motor below the Level of Injury
- Bulbocavernous Reflex

Scott Weingart, MD

Anterior

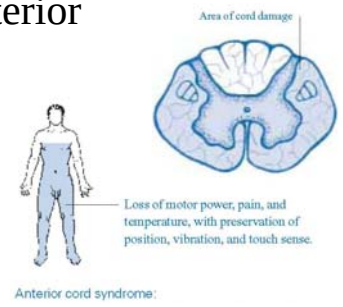

The First 48 Hours. Spinal Injury Association. http://www.spinal.co.uk/

Posterior

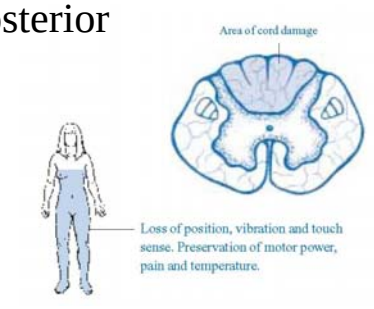

The First 48 Hours. Spinal Injury Association. http://www.spinal.co.uk/

Hemi-Section

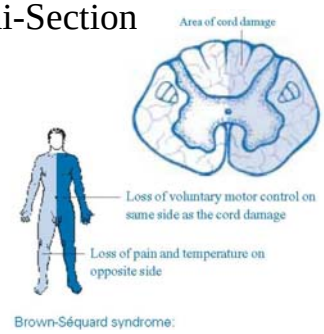

The First 48 Hours. Spinal Injury Association. http://www.spinal.co.uk/

Central

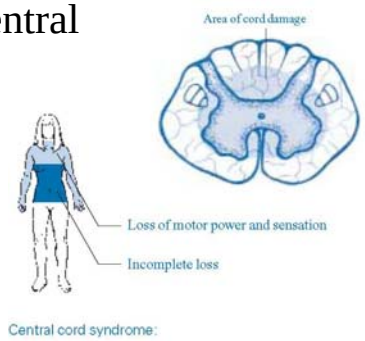

The First 48 Hours. Spinal Injury Association. http://www.spinal.co.uk/

SCI Procedure

Maintain Blood Pressure at All Times

Scott Weingart, MD

SCI Procedure

Push that MAP

Scott Weingart, MD

MAP Push

May need fluids, pressors, inotropes, and/or blood

Scott Weingart, MD

SCI Procedure

Beware of the Vagus

Scott Weingart, MD

Vagal Precautions

Be careful when suctioning and intubating.

Keep atropine at bedside

Scott Weingart, MD

SCI Procedure

Intubate Early / Intubate Safely

Scott Weingart, MD

Patient Outcome

- Received Anterior & Posterior Fixation
- Received Tracheostomy
- MAPS maintained for 1 week
- Weaned to Trach Collar
- Intensive OT/PT/Psych Support
- Discharged to Acute Rehab Day 9

Scott Weingart, MD

Further Reading

Guidelines for the Management of Acute Cervical Spine and SCI. *Neurosurg 2002;*50(3):suppl-1-200

Valadka AB. *Neurotrauma: Evidence-Based Answers To Common Questions.*

UK Spinal Injuries Association. *The First 48-hours*. http://www.spinal.co.uk/

Scott Weingart, MD

Questions??

www.ferne.org
ferne@ferne.org

Scott Weingart, MD
gatsby@eudoramail.com
817.977.3384

Ferne_2006_aaem_sa_weingart_bic_spine.ppt

Scott Weingart, MD