
Optimizing Headache Management in the ED: *A Focus on Subarachnoid Hemorrhage*



Scott Silvers, MD, FACEP



Scott Silvers, MD, FACEP

Assistant Professor

*Co-Director Primary Stroke Center
Department of Emergency Medicine
Mayo Clinic College of Medicine
Jacksonville, Florida*



Scott Silvers, MD, FACEP



Objectives

- Improve evaluation of patients for SAH
- Learn key points in diagnosis, treatment disposition, documentation
- Improve outcome of patients with SAH
- Further Emergency Medicine practice as it relates to SAH



Scott Silvers, MD, FACEP



Methods

- Case presentation
- Discussion of critical questions
- State current recommendations
- Review how we diagnose SAH
- Evaluate patient outcome
- Review ED documentation



Scott Silvers, MD, FACEP



A Clinical Case

Scott Silvers, MD, FACEP



Patient Clinical History

- 47 yo female
- Shopping with her husband
- Severe, sudden onset of headache
- Sat down → passed out for 3-5 minutes
- Hx of HTN on diuretic

Scott Silvers, MD, FACEP



ED Presentation

- Vitals: 99.5F, 105, 16, 190/95, 98% RA
- Lying still on stretcher with eyes closed
- NCAT, Heart, lungs, abdomen normal
- “Sore” neck, no clear meningismus
- Alert, mild confusion
- CN intact, strength 5/5 all 4 ext, sensory intact, DTRs normal, FTN normal

Scott Silvers, MD, FACEP 

Clinical Questions

- Who is at risk for SAH?
- What symptoms suggest SAH?
- How can we best diagnose SAH?
- Who requires CT? LP? Angiography?
- When should an LP be deferred?
- When is “traumatic tap” the likely diagnosis?
- When does symptom resolution suggest a benign headache etiology?

Scott Silvers, MD, FACEP 

Headache in the ED: Evidence-based Recommendations



Scott Silvers, MD, FACEP 

Grading of Recommendations

Level A recommendations. Generally accepted principles for patient management that reflect a high degree of clinical certainty (ie, based on “strength of evidence class I” or overwhelming evidence from “strength of evidence class II” studies that directly address all the issues).

Level B recommendations. Recommendations for patient management that may identify a particular strategy or range of management strategies that reflect moderate clinical certainty (ie, based on “strength of evidence class II” studies that directly address the issue, decision analysis that directly addresses the issue, or strong consensus of “strength of evidence class III” studies).

Level C recommendations. Other strategies for patient management that are based on preliminary, inconclusive, or conflicting evidence or, in the absence of any published literature, based on panel consensus.



Scott Silvers, MD, FACEP 

ACEP Policy: Acute Headache

- Does a response to therapy predict the etiology of an acute headache?
 - Level C:
 - Pain response to therapy should not be used as the sole diagnostic criteria in determining the underlying etiology of an acute headache.

Ann Emerg Med, Jan 2002; 39:108-122

Scott Silvers, MD, FACEP 

ACEP Policy: Acute Headache

- In which adults with a headache can an LP be safely performed without neuroimaging?
 - Level C:
 - Those pts without signs of increased intracranial pressure (ICP) e.g.
 - Papilledema, absent venous pulses
 - Altered mental status
 - Focal neurologic deficits

Ann Emerg Med, Jan 2002; 39:108-122

Scott Silvers, MD, FACEP 

ACEP Policy: Acute Headache

- Which patients with an acute headache require neuroimaging?
 - Level B:
 - Headache and focal neurologic deficit
 - Headache of sudden, rapid onset (e.g SAH)
 - HIV and new headache
 - Level C:
 - > 50 years old, new or different headache

Ann Emerg Med, Jan 2002; 39:108-122

Scott Silvers, MD, FACEP



ACEP Policy: Acute Headache

- Do patients with “thunderclap” headache need an angiogram after a negative CT and LP?
 - Level C:
 - No, outpatient follow-up if:
Negative CT, normal opening pressure, and “negative” CSF analysis

Ann Emerg Med, Jan 2002; 39:108-122

Scott Silvers, MD, FACEP

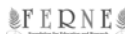

Sentinel Headache in SAH

- Incidence: ED HA patients = 1/1000
- Present in 10-43% of SAH patients
- Typically occurs 2 weeks prior to SAH
- Unusual, severe, abrupt, thunderclap
- Xanthochromia after first 12 hours

Neuro Sci (2004) 25:S 215-217

Scott Silvers, MD, FACEP



Sentinel Headache: Symptoms

- 77% Nausea/Vomiting
- 74% Severe, sudden onset
- 64% Focal neuro deficit
- 53% Syncope
- 33% Stiff neck

Neuro Sci (2004) 25:S 215-217

Scott Silvers, MD, FACEP

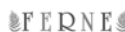

“Worst Headache of My Life”

- N= 107 patients “worst headache”
- 20 pts with SAH (19.5%)
- 18 of 20 diagnosed by CT (90%)
- Two diagnosed: + LP after - CT
- NPV of CT = 87/89 = 98%
(2% would have SAH)

Ann Emer Med, Sept 1998; 32: 297-304

Scott Silvers, MD, FACEP

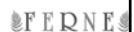

“Worst Headache” LP Results

- Positive LP, Negative CT (n=2)
 - Tube 1 RBCs: 163,000 median
 - Tube 4 RBCs: 221,000 median
- Negative LP, Negative CT (N = 77)
 - Tube 1 RBCs: 19 median
 - Tube 4 RBCs: 0 median

Ann Emer Med, Sept 1998; 32: 297-304

Scott Silvers, MD, FACEP



Fifth Generation CT and SAH

- 2002 Retrospective study
- N = 177 with possible SAH
- All pts had both CT and LP
- “Fifth generation” CT scanner
- “Negative LP” = Tube 1 <400 RBCs and 10-fold drop by tube 4

JEM, 2005; 29: 23-27

Scott Silvers, MD, FACEP



Fifth Generation CT and SAH

- Results:
 - 6 CT scans positive for SAH
 - No CT neg pts had a positive LP
- Conclusion:
 - 5th gen CT detects SAH accurately
 - 100% sensitivity (61-100%)
 - 99.4% specificity (97-100%)

JEM, 2005; 29: 23-27

Scott Silvers, MD, FACEP



SAH: *The Evaluation*

Scott Silvers, MD, FACEP



SAH: The Evaluation

- Evaluate ABCs, altered mental status

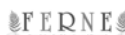Scott Silvers, MD, FACEP



SAH: The Evaluation

- Evaluate ABCs, altered mental status
- Know SAH risk factors:
 - Hypertension, DM, prior aneurysm/SAH
 - Thunderclap headache
 - Maximum severity in minutes
 - Focal neurological deficit

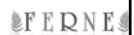Scott Silvers, MD, FACEP



Non-contrast CT Head

- Inform radiologist to rule out SAH
- CT should be performed with sufficiently thin cuts (3 – 5 mm cuts)
- Unlikely to miss SAH on CT if performed and interpreted well

Scott Silvers, MD, FACEP



SAH: The Evaluation

- How do we evaluate a CT for SAH?

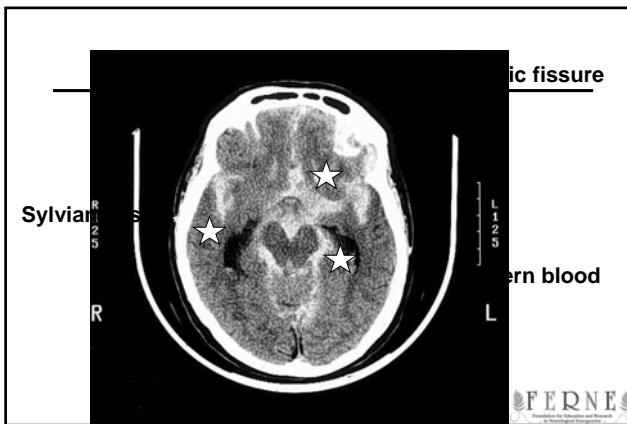
Scott Silvers, MD, FACEP



SAH: CT Interpretation

- CT evaluation for subarachnoid blood
 - 1) Inter-hemispheric fissure
 - 2) Inferior frontal sulci
 - 3) Third ventricle
 - 4) Ambient cistern
 - 5) Sylvian fissure

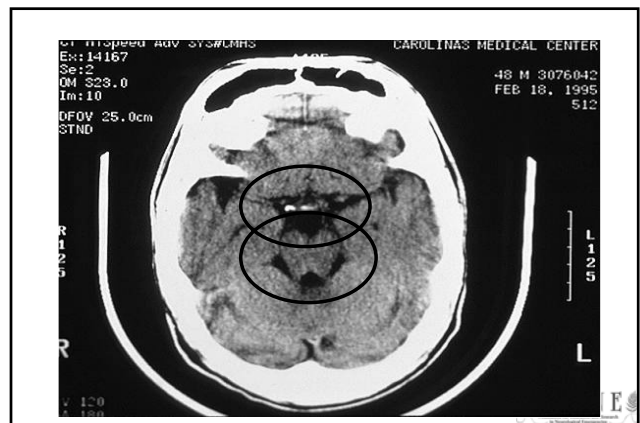
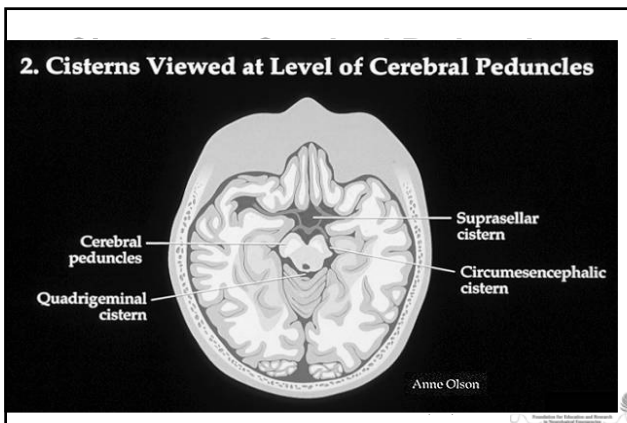
Scott Silvers, MD, FACEP



CT Interpretation: Elevated ICP

- CT findings that exclude elevated ICP
 - Normal cisterns
 - No obliteration of cistern space
 - No edema, mass effect, or midline shift
 - No hydrocephalus

Scott Silvers, MD, FACEP



Symptom Resolution

- Can headache resolution be used to exclude SAH?
- Brings to mind another question....
In a patient who presents to the ED with a headache, can you rule out SAH by clinical evaluation alone?

Scott Silvers, MD, FACEP 

Symptom Resolution

- Consider headaches likely benign if:
- Low risk SAH patient
 - No focal neurological findings
 - Complete symptom resolution with meds that effectively treat migraine and muscle-tension headache (i.e. non-narcotic)

Scott Silvers, MD, FACEP 

Lumbar Puncture Need

Which patients should have a lumbar puncture?

Scott Silvers, MD, FACEP 

Lumbar Puncture Indications

- Moderate to high risk SAH patients following negative CT
- Severe, abrupt, thunderclap headache
- Focal neurological findings
- Unknown CT protocol / interpretive quality
- Minimal symptom resolution with meds that effectively treat migraine and muscle-tension headache

Scott Silvers, MD, FACEP 

Deferred Lumbar Puncture

- Is it sometimes reasonable to not perform a lumbar puncture on patients suspected of SAH?

Scott Silvers, MD, FACEP 

Deferred Lumbar Puncture

- Positive CT
 - Evidence of elevated ICP, edema, mass effect, midline shift, ICH, hydrocephalus
- Technically difficult procedure
- Critically ill or unstable patient
- Coagulopathy

Scott Silvers, MD, FACEP 

Measuring Opening Pressure

- Is it necessary to measure opening pressure when performing an LP?

Scott Silvers, MD, FACEP 

Measuring Opening Pressure

- Variable practice....
 - Measure if CSF flowing rapidly
 - Consider measuring with every LP

Scott Silvers, MD, FACEP 

SAH: The Evaluation

- How should we interpret CSF results?

Scott Silvers, MD, FACEP 

Interpreting CSF: RBCs

- Likely SAH with:
 - 10,000-100,000 RBCs or greater
 - No clearing of RBCs in tube 4
- Consider possible SAH with:
 - Intermediate RBC count (1,000 – 10,000)
 - Little RBC clearing by tube 4
- Traumatic tap
 - 75-90% drop in RBCs from tube 1 to 4

Scott Silvers, MD, FACEP 

CSF Xanthochromia

- Xanthochromia characteristics
 - Typically > 12 hours from headache onset
 - Quantitative and qualitative measurements
 - “Read news print test” most often used
 - Clears after weeks

Scott Silvers, MD, FACEP 

SAH: The Evaluation

- When is angiography indicated?

Scott Silvers, MD, FACEP 

SAH: Cerebral Angiography

- **Cerebral angiography indications:**
 - High risk patients with uncertain diagnosis
 - Interventional radiology available for coiling
 - Preoperative neurosurgical planning
- **MRI, MRA, CTA need less well established**

Scott Silvers, MD, FACEP 

SAH: Treatment

- **How should we treat patients with SAH?**

Scott Silvers, MD, FACEP 

Treating SAH Patients

- **SAH with increased ICP:**
 - Head of the bed at 45 degrees
 - Mannitol 20% solution 0.25-1.0g per Kg
 - Hyperventilation to pCO₂ 30-35 mmHg, temporizing, only if other measures fail
 - Ventriculostomy
 - Consider seizure prophylaxis
 - Nimodopine (vasoconstriction prophylaxis)

Scott Silvers, MD, FACEP 

ED Case Patient Outcome

Scott Silvers, MD, FACEP 

ED Patient Management

- Pt had a generalized tonic-clonic seizure
- Responded to benzodiazapines
- Return to normal mental status

Scott Silvers, MD, FACEP 

ED Diagnostic Evaluation

- **Non-contrast CT negative**
- **Metabolic, toxicology tests normal**
- **CSF:**
 - Tube 1 = 355,000 RBCs
 - Tube 4 = 298,000 RBCs
- **Diagnosis: Subarachnoid Hemorrhage**

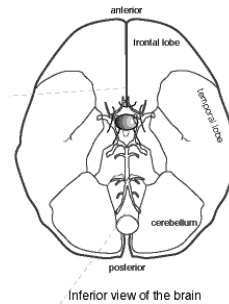
Scott Silvers, MD, FACEP 

Patient Outcome

- Cerebral angiogram performed
- Saccular aneurysm in the posterior communicating artery
- Neurosurgical aneurysm clipping
- Pt was discharged in one week
- No residual neurological deficit

Scott Silvers, MD, FACEP 

Patient Outcome



Scott Silvers, MD, FACEP 

Questions??

www.ferne.org
ferne@ferne.org

Scott Silvers, MD, FACEP
silvers.scott@mayo.edu
(904) 296 - 5741



ferne_2005_acep_sa_silvers_BIC_SAH_fshow

Scott Silvers, MD, FACEP 