

Stroke

American Stroke
AssociationSM

JOURNAL OF THE AMERICAN HEART ASSOCIATION

A Division of American
Heart Association



MERCI 1: A Phase 1 Study of Mechanical Embolus Removal in Cerebral Ischemia

Y. Pierre Gobin, Sidney Starkman, Gary R. Duckwiler, Thomas Grobelny, Chelsea S. Kidwell, Reza Jahan, John Pile-Spellman, Alan Segal, Fernando Vinuela and Jeffrey L. Saver

Stroke 2004;35;2848-2854; originally published online Oct 28, 2004;

DOI: 10.1161/01.STR.0000147718.12954.60

Stroke is published by the American Heart Association, 7272 Greenville Avenue, Dallas, TX 75214
Copyright © 2004 American Heart Association. All rights reserved. Print ISSN: 0039-2499. Online
ISSN: 1524-4628

The online version of this article, along with updated information and services, is located on the World Wide Web at:

<http://stroke.ahajournals.org/cgi/content/full/35/12/2848>

Subscriptions: Information about subscribing to Stroke is online at
<http://stroke.ahajournals.org/subscriptions/>

Permissions: Permissions & Rights Desk, Lippincott Williams & Wilkins, 351 West Camden Street, Baltimore, MD 21202-2436. Phone 410-5280-4050. Fax: 410-528-8550. Email:
journalpermissions@lww.com

Reprints: Information about reprints can be found online at
<http://www.lww.com/static/html/reprints.html>

MERCI 1

A Phase 1 Study of Mechanical Embolus Removal in Cerebral Ischemia

Y. Pierre Gobin, MD; Sidney Starkman, MD; Gary R. Duckwiler, MD; Thomas Grobelny, MD;
Chelsea S. Kidwell, MD; Reza Jahan, MD; John Pile-Spellman, MD; Alan Segal, MD;
Fernando Vinuela, MD; Jeffrey L. Saver, MD

Background and Purpose—To report the result of the Mechanical Embolus Removal in Cerebral Ischemia (MERCI) 1 study, a phase 1 trial to evaluate the safety and efficacy of mechanical embolectomy in the cerebral vasculature.

Methods—MERCI 1 enrolled 30 patients in 7 US centers. Main inclusion criteria were: National Institutes of Health Stroke Scale score (NIHSS) ≥ 10 ; treatment performed within 8 hours from symptoms onset and contra-indication to intravenous thrombolysis; no large hypodensity on computed tomography; and occlusion of a major cerebral artery on the angiogram. Safety was defined by the absence of vascular injury or symptomatic intracranial hemorrhage. Efficacy was assessed by recanalization rate and clinical outcome at 1 month. Significant recovery was defined as 30-day modified Rankin of 0 to 2 in patients with baseline NIHSS 10 to 20 and 30-day modified Rankin of 0 to 3 in patients with baseline NIHSS >20 . The procedures were performed with the Merci Retrieval System, a system specially designed for intracranial embolectomy.

Results—Twenty-eight patients were treated. Median NIHSS was 22. Median time from onset to completion of treatment was 6 hours and 15 minutes. Successful recanalization with mechanical embolectomy only was achieved in 12 (43%) patients, and with additional intra-arterial tissue plasminogen activator in 18 (64%) patients. There was one procedure related technical complication, with no clinical consequence. Twelve asymptomatic and no symptomatic intracranial hemorrhages occurred. At 1 month, 9 of 8 revascularized patients and 0 of 10 nonrevascularized patients had achieved significant recovery.

Conclusion—This phase 1 study shows that cerebral embolectomy with the Merci Retriever was safe and that successful recanalization could benefit a significant number of patients, even when performed in an extended 8-hour time window. (*Stroke*. 2004;35:2848-2854.)

Key Words: embolectomy ■ stroke, ischemic ■ thrombectomy ■ thrombolytic therapy

In 1995, the National Institute of Neurological Disorders and Stroke trials showed that intravenous tissue plasminogen activator (tPA) given within 3 hours from symptoms onset benefited stroke patients despite a 6.4% risk of symptomatic intracranial hemorrhage. However, although intravenous tPA was approved by the FDA in 1996 for treatment of stroke, only 2% to 3% of US stroke patients currently receive this treatment,¹ mostly because of the limited therapeutic time window of 3 hours.²

See Editorial Comment, page 2853

Extending this brief time window is critical for the majority of stroke patients to benefit from arterial recanalization. However, the risk-to-benefit ratio of intravenous tPA becomes rapidly unfavorable as time elapses, because less brain tissue can be saved while the risk of cerebral hemorrhage increases. Four clinical trials showed no benefit when intravenous tPA was given after 3 hours,³⁻⁶ and even in the NINDS trial most of the

Received February 12, 2004; accepted September 17, 2004.

From the Division of Interventional Neuroradiology (Y.P.G.), Weill Cornell Medical College, New York Presbyterian Hospital, New York, NY; the UCLA Stroke Study Network (S.S.), UCLA Fellowship in Stroke and Cerebrovascular Disorders, UCLA Emergency Medicine Center, Los Angeles, Calif; the Division of Interventional Neuroradiology (G.R.D.), Department of Radiological Sciences, University of California Los Angeles; Neurointerventional Surgery (T.G.), Saint Luke's Hospital, Department of Radiology, Kansas City, Mo; the UCLA Stroke Unit and Comprehensive Stroke and Vascular Neurology Program (C.S.K.), Department of Neurology, UCLA School of Medicine, Reed Neurological Research Center, Los Angeles, Calif; the Division of Interventional Neuroradiology (R.J.), Department of Radiological Sciences, University of California Los Angeles; the Department of Radiology, Neurosurgery, and Neurology (J.P.-S.), Columbia University, Milstein Hospital, New York, NY; the Department of Neurology (A.S.), Weill Cornell Medical College, New York Presbyterian Hospital, New York, NY; the Department of Radiological Sciences (F.V.), UCLA Medical Center, Los Angeles, Calif; the UCLA Stroke Unit and Comprehensive Stroke and Vascular Neurology Program (J.L.S.), Department of Neurology, UCLA School of Medicine, Los Angeles, Calif.

Y.P.G. is the co-inventor of the MERCI Retriever; he is a director, medical advisor, and holds stocks in Concentric Medical. G.R.D. is a medical advisor and holds stocks in Concentric Medical, Inc. The MERCI 1 study was funded by Concentric Medical, Inc, 1380 Shorebird Way, Mountain View, Calif.

Correspondence to Dr Y. Pierre Gobin, 525 East 68th Street, Box 141, New York Presbyterian Hospital, New York, NY 10021. E-mail yvg2001@med.cornell.edu

© 2004 American Heart Association, Inc.

Stroke is available at <http://www.strokeaha.org>

DOI: 10.1161/01.STR.0000147718.12954.60




Figure 1. After the microcatheter trans-
verses the thrombus, the first loops of
the Merci Retriever are delivered distal to
the occlusion site.

benefit of tPA over placebo was observed in the patients treated within 90 minutes from stroke onset.

Intra-arterial thrombolysis offered the hope of lengthening the time window for treatment. The PROACT II study of intra-arterial thrombolysis showed mild benefit when pro-urokinase was given within 6 hours of symptom onset despite a 10% rate of symptomatic intracranial hemorrhage.⁷ The FDA would not approve pro-urokinase unless a larger trial (PROACT 3) is performed, which is unlikely to occur.²

In an attempt to prolong the therapeutic time window and to treat patients with contra-indications to thrombolysis, we developed a mechanical system for endovascular embolectomy. Embolectomy should decrease the risk of hemorrhage because no (or minimal) thrombolytics are used, allowing the treatment of patients in a prolonged time window. Mechanical recanalization of the cerebral arteries presents unique challenges. Therefore, we designed the Merci Retrieval System specifically for percutaneous thromboembolectomy in brain vasculature. Here, we present the results of the phase 1 safety study in 30 patients.

Materials and Methods

Study Design

MERCI 1 was designed to evaluate the safety and technical efficacy of embolectomy in the cerebral arteries with the Merci Retriever in 30 consecutive patients. The study was performed in 7 US centers between May 16, 2001 and October 17, 2002, and the protocol was approved by the FDA under an international device exemption study, and by the institutional review boards at each center.

Patients were included for the trial if they: (1) had an acute ischemic stroke with NIHSS ≥ 10 ; (2) presented after the 3-hour time window for intravenous thrombolysis and could be treated within 8 hours of symptom onset; (3) presented within 3 hours of symptom onset with a contraindication to intravenous thrombolysis; (4) were older than age 18; and (5) had a normal computed tomography (CT) scan or a CT scan showing a region of hypodensity less than one-third of the middle cerebral artery territory. Patients were excluded with: (1) glucose < 50 mg/dL; (2) seizure at onset of stroke; (3) known prothrombin time > 15 or hemorrhagic diathesis, coagulation factor deficiency, or oral anticoagulation therapy with international normalized ratio (INR) > 3.0 ; (4) use of heparin within 48 hours with a partial thromboplastin time > 2 times normal; (5) platelets $< 50,000$; (6) severe hypertension defined as systolic blood pressure > 185 or diastolic blood pressure > 110 ; and (7) a CT scan revealing significant mass effect with midline shift.

Patients who met all clinical and CT scan criteria and for whom informed consent was obtained underwent cerebral angiography. Patients were then selected for embolectomy if the diagnostic angiogram showed an occlusion of the internal carotid artery, M1 segment of the middle cerebral artery, basilar artery, or vertebral artery. Patients were excluded if the angiogram showed a severe

arterial stenosis proximal to the thrombus that, in the opinion of the investigator, would preclude thrombus removal.

Primary outcome was defined as arterial recanalization thrombolysis in myocardial infarction (TIMI; grade 2 or 3) without the occurrence of major complications defined as vessel perforation, arterial dissection, or embolization in a previously uninvolved territory. Secondary outcomes included the incidence of hemorrhage as determined by a head CT scan obtained at 24 hours, with a hemorrhage considered symptomatic if it was associated with a clinical deterioration of > 4 points on the NIHSS, and NIHSS and modified Rankin score at 24 hours, 5 days, and 30 days after ictus. A significant recovery was defined as a 30-day modified Rankin score of 0 to 2 in patients with a baseline NIHSS of 10 to 20, and a 30-day modified Rankin score of 0 to 3 in patients with a baseline NIHSS > 20 .

The Merci Retrieval System

The Merci Retrieval System (Concentric Medical) consists of the Merci Retriever, the Merci Balloon Guide Catheter (BGC), and the Merci microcatheter. The BGC is a 9-French catheter with a large 2.1-mm lumen and a balloon located at its distal tip. The Merci Retriever uses superelastic technology, ie, the superelastic property of memory shaped nitinol (nickel titanium). The Merci Retriever is a tapered wire with 5 helical loops of decreasing diameter (from 2.8 mm to 1.1 mm) at its distal end. The Merci Retriever is advanced through the microcatheter in its straight configuration and resumes its pre-imposed helical shape once it is delivered into the occluded intracranial artery in order to ensnare the thrombus.

Procedure

Enrolled patients were given a bolus of 3000 U of heparin intravenously. The BGC was placed into the common or internal carotid artery for anterior circulation occlusion, or the subclavian artery for posterior circulation occlusion. Using standard catheterization techniques, the microcatheter was guided into the occluded vessel and passed beyond the thrombus. A selective angiogram was performed distal to the thrombus to evaluate the size and tortuosity of the distal arteries, where the Merci Retriever was to be deployed. The Merci Retriever was then advanced through the microcatheter and 2 to 3 helical loops were deployed beyond the thrombus (Figure 1). The Merci Retriever was then retracted at the contact of the thrombus, and the proximal loops were then deployed within the thrombus (Figure 2). The BGC balloon was inflated to control intracranial blood flow during removal of the thrombus and 5 clockwise rotations were applied to the Merci Retriever to further ensnare the thrombus (Figure 3). The Merci Retriever with the ensnared thrombus, and the microcatheter, were withdrawn together into the BGC lumen. Continuous aspiration was applied to the BGC to ensure complete evacuation of the thrombus. The balloon of the BGC was deflated to re-establish flow. On confirmation of complete evacuation of the thrombus (brisk reflux of blood), a repeat angiogram was performed. If the occlusion persisted, then the procedure could be repeated up to 6 passes of the Merci Retriever. If it was unable to restore flow, then additional treatment was left at the



Figure 2. The Merci Retriever is pulled
back at the contact of the thrombus,
additional loops are delivered within the
thrombus, and the Merci Retriever is
torqued to ensnare the thrombus.

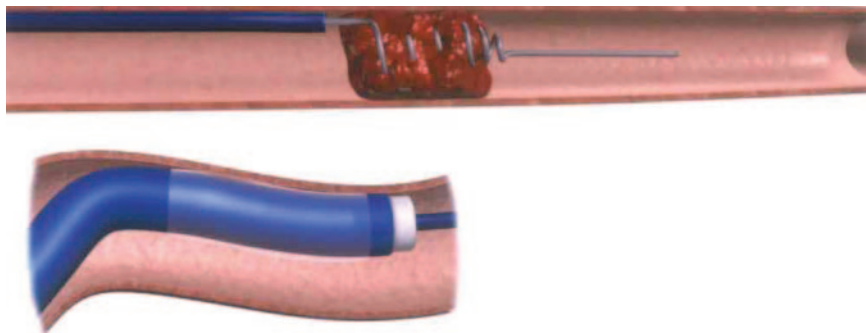


Figure 3. The balloon of the balloon guide catheter (BGC) (insert) is inflated to control antegrade flow, and the Merci Retriever is pulled back with the ensnared thrombus toward the tip of the BGC where it is aspirated.

discretion of the interventionalist. Figure 4 shows an example of thrombi removed from a carotid T occlusion (patient 9).

Results

Thirty patients were included in the study, and of these, 2 patients were enrolled but not treated. In one patient, visualization under fluoroscopy discovered that the thrombus extended into the M2 segment of the middle cerebral artery, and in the other patient the Merci Retriever was unable to get to the site of the thrombus because of tortuous anatomy.

Of the 28 patients treated, there were 14 males (50%) with a mean age of 68 (range, 28 to 93). Median baseline NIHSS was 22 (range, 12 to 39). Six patients presented within 3 hours of symptoms onset but had contraindication for intravenous tPA, and 21 patients presented between 3 and 8 hours after symptoms onset. One patient was treated outside the 8-hour time window (11 hours) because of a large diffusion/perfusion mismatch on MRI.

Occluded arteries included the intracranial internal carotid artery in 5 (18%), middle cerebral artery in 18 (64%), both internal carotid artery and middle cerebral artery in 3 (11%), and vertebro-basilar in 2 (7%) patients.

The median and mean time from baseline CT to groin puncture was 2 hours 23 minutes and 2 hours 29 minutes,




Figure 4. Photograph showing the Merci Retriever and the 2 thrombi, which were retrieved in case 9. The scale is in centimeters. One thrombus measured 10 mm×4 mm, the second measured 4 mm×4 mm.

respectively. The median and mean time from groin puncture to completion of treatment was 1 hour 14 minutes and 1 hour 27 minutes, respectively. The median and mean time of stroke symptom onset to completion of treatment were 6 hours 15 minutes and 6 hours 1 minute, respectively.

Two patients (7%) received only magnetic resonance imaging and no CT scan before to enrollment. There were 3 (11%) protocol deviations with regard to prothrombin time. These 3 patients had a prothrombin time >15 seconds; however, their INR was <3, as required by protocol.

Successful recanalization (TIMI 2 to 3) was achieved in 12 (43%) patients with the Merci Retriever only. Eight patients (29%) received intra-arterial tPA after unsuccessful recanalization. Six had successful recanalization (TIMI 2 or 3) after administration of the drug.

With additional intra-arterial tPA, successful recanalization was obtained in 18 (64%) patients.

Table 1 gives, for each patient, the NIHSS score, recanalization, possible treatment with thrombolysis, NIHSS, and modified Rankin score at 24 hours, 5 days, and 30 days.

Table 2 presents patient outcome dichotomized according to baseline NIHSS (10 to 20 or >20) and recanalization. In the 13 patients who presented with moderate to severe stroke (NIHSS 10 to 20), 6 out of 10 revascularized patients achieved significant recovery (modified Rankin score 0 to 2), whereas none of the 3 patients who were not revascularized achieved significant recovery. In the 15 patients who presented with very severe stroke (NIHSS >20), 3 out of 8 revascularized patients achieved significant recovery (modified Rankin score 0 to 3), whereas none of the 7 patients who were not revascularized achieved significant recovery. Overall, 9 of 18 (50%) revascularized patients and 0 of 10 nonrevascularized patients achieved significant recovery.

There was one technical complication when the tip of the Merci Retriever detached from the device. Another Merci Retriever was used to ensnare the detached tip and successfully remove it from the vasculature. This had no clinical consequence.

There were 10 deaths (36%) during the 30-day follow-up period. These patients died from 1 to 28 days after the procedure (mean, 6 days). All deaths were determined to be related to the disease state of the patient and not to the study device.

Twelve patients (43%) had asymptomatic intracranial hemorrhages discovered on the 24-hour CT scan required per protocol. There were no symptomatic hemorrhages.

TABLE 1. Patient Outcomes

Patient	NIHSS Pretreatment	Artery Occluded	TIMI After Embolectomy	IA t-PA (dose)	TIMI After	NIHSS 5 Days	NIHSS 30 Days	Rankin 30 Days
					Embolectomy and Thrombolysis			
1	19	ICA	III	n/a	n/a	1	2	0
2	26	ICA	I	n/a	n/a	30	Death	6
3	25	MCA	0	n/a	n/a	21	16	4
4	14	MCA	0	15 mg	III	0	0	0
5	24	MCA	I	n/a	n/a	Death	Death	6
6	13	MCA	0	7 mg	III	4	2	2
7	18	ICA+MCA	II	n/a	n/a	20	37	5
8	19	MCA	0	n/a	n/a	15	16	5
9	26	ICA+MCA	II	n/a	n/a	12	9	3
10					Not Treated			
11	16	MCA	II	n/a	n/a	4	0	0
12	39	Vertebral	I	n/a	n/a	19	7	4
13	19	MCA	I	n/a	n/a	18	8	4
14	17	ICA+MCA	II	n/a	n/a	22	Death	6
15	38*	MCA	II	n/a	n/a	16	11	4
16	23	MCA	II	n/a	n/a	23	20	5
17					Not Treated			
18	22	MCA	0	n/a	n/a	Death	Death	6
19	29	MCA	III	n/a	n/a	15	15	3
20	18	MCA	0	6 mg	II	12	9	3
21	24	MCA	II	n/a	n/a	Death	Death	6
22	36	Basilar	I	n/a	n/a	Death	Death	6
23	16	MCA	0	20 mg	I	25	13	5
24	12	ICA	III	n/a	n/a	0	0	0
25	17	ICA	III	n/a	n/a	Death	Death	6
26	28	MCA	I	20 mg	II	Death	Death	6
27	21	ICA	0	15 mg	0	Death	Death	6
28	26	ICA	0	10 mg	II	37	Death	6
29	23	MCA	I	20 mg	III	13	6	3
30	15	MCA	III	n/a	n/a	0	0	0

*NIHSS performed on sedated patient.

N/a indicates not available; MCA, middle cerebral artery; ICA, internal cerebral artery.

Discussion

This study shows that embolectomy with the Merci Retriever was safe. There was no angiographic or clinical evidence of vascular injury or emboli into previously uninvolved arteries. Successful recanalization with thrombectomy

alone was obtained in 43%. The total recanalization rate, including those patients successfully revascularized with intra-arterial thrombolytics, was 64%. Among the 18 patients who were revascularized, 50% (9/18) made a significant recovery (defined as 30-day modified Rankin

TABLE 2. NIHSS and Recanalization vs Outcome

Baseline NIHSS	Recanalization*	Modified Rankin Score, 30 Days						
		0	1	2	3	4	5	6
NIHSS 10–20	Yes	5	0	1	1	0	1	2
	No	0	0	0	0	1	2	0
NIHSS >20	Yes	0	0	0	3	1	1	3
	No	0	0	0	0	2	0	5

*Recanalization: revascularization (TIMI II-III) obtained after embolectomy and intra-arterial t-PA.

Bold numbers indicate significant recovery (modified Rankin score 0 to 2 when baseline NIHSS 10 to 20 and modified Rankin score 0 to 3 when baseline NIHSS >20). Significant recovery was observed in 9 of 18 recanalized patients and 0 of 10 nonrecanalized patients.

score 0 to 2 in patients with baseline NIHSS 10 to 20 and 30-day modified Rankin score 0 to 3 in patients with baseline NIHSS >20). In contrast, of the 10 patients not revascularized, none made a significant recovery. There were no symptomatic hemorrhages.

Treating ischemic stroke by embolectomy is not a new concept. The first surgical embolectomies of intracranial arteries were reported in 1956 by Welch.⁸ In the next decades, multiples small series were reported, mostly involving embolectomy in the middle cerebral artery.⁹ Despite early successful experience, surgical embolectomy never became a mainstream procedure because it was too invasive and only expert neurosurgeons could perform it quickly enough.

An endovascular approach to embolectomy would solve these issues if the procedure could be performed easily and quickly. However, there is currently no device designed for endovascular embolectomy of the cerebral arteries. The Fogarty embolectomy balloon catheter has been widely used for embolectomy in the cervical internal carotid artery from a cervical arteriotomy, but it is rather traumatic when used in the intracranial internal carotid, with a risk of carotid cavernous fistulas or dissections.^{10–12} Several case reports were recently published of percutaneous intracranial embolectomy using a gooseneck microsnare^{13,14} or the Neuronet device¹⁵ with good results. Although these systems were developed for retrieving foreign bodies and not for thrombo-embolectomy, this initial good experience shows that the concept of endovascular embolectomy is sound. Other techniques are being developed to recanalize cerebral arteries by pure mechanical action or by facilitating the action of thrombolytic drugs, including rheolytic thrombectomy, laser, or ultrasound. Phase I safety trials have been promising, despite difficulties caused by the tortuosity and fragility of intracranial arteries and the heterogeneity in the composition of the emboli.^{16–18}

A potential risk of embolectomy is thrombus fragmentation. This risk has been minimized in this study by using a BGC. During thrombus retrieval, the balloon on the BGC is inflated to stop antegrade blood flow, reducing flow-induced shear stress and potential fragmentation of the thrombus or detachment of the thrombus from the Merci Retriever. No embolization into previously open arteries was observed in this study. However, it is not possible to know if embolization in arteries distal to the initial thrombo-occlusion occurred. This is because, in most circumstances, the baseline angiogram shows only the proximal occlusion without evaluating the permeability of the distal arteries. Although undesirable, a distal embolization into a previously occluded territory is in most cases a better clinical situation than the initial occlusion. This is frequently observed during intra-arterial thrombolysis, in which thrombolysis decreases the size of the thrombus, which then migrates more distally.

In Mechanical Embolus Removal in Cerebral Ischemia (MERC1) 1 we enrolled patients who presented after the 3-hour time window for intravenous thrombolysis in which embolectomy could be achieved within 8 hours of symptom onset. We chose this 8-hour time window because of the results of the PROACT II study. In PROACT II, the maximal time from onset to starting the thrombolysis was 6 hours (median 5.3 hours). The infusion time of pro-urokinase was 2

hours, making the maximal time from symptom onset to recanalization 8 hours. As PROACT II demonstrated benefit from intra-arterial thrombolysis despite a 10% symptomatic hemorrhage rate, we postulated that embolectomy could be beneficial even in an extended time window of 8 hours. The second population of MERC1 1 was patients who presented within 3 hours of stroke onset but in whom intravenous thrombolysis was contraindicated. We postulated that embolectomy would be beneficial in these patients because it would not increase the risk of hemorrhage.

Only patients with moderate to severe stroke were enrolled in the MERC1 1 study. An NIHSS ≥ 10 was chosen because these patients generally have a poor outcome and small chance of spontaneous good recovery.^{19,20} An NIHSS ≥ 10 is also selective for patients with large vessel occlusion at angiography. In the Emergency Management of Stroke study, 78% of patients with an NIHSS ≥ 10 and only 33% of patients with an NIHSS < 10 had an arterial occlusion at angiography.²⁰ The phase 2 MERC1 study, a prospective study of efficacy of embolectomy in 150 patients with moderate and severe stroke, is currently underway in 25 US centers. If it confirms the results of MERC1 1, then mechanical embolectomy with the Merci Retriever could address the major drawback of intravenous or intra-arterial thrombolysis, namely that the risk of hemorrhage compared with the potential benefit of revascularization becomes rapidly unacceptable when the time window is extended beyond 3 hours. Although the number of patients in this phase 1 study is small, these results suggest that mechanical embolectomy performed within 8 hours from symptom onset in moderate and severe stroke may benefit half the cohort of successfully recanalized patients with minimal risk of symptomatic hemorrhage or device-related complications.

Acknowledgments

MERC1 1 Clinical Sites and Investigators (in order of recruitment) University of California Los Angeles (14 cases): S. Starkman, G. R. Duckwiler, Y. Pierre Gobin, R. Jahan, C. S. Kidwell, M. Leary, N. Martin, J. L. Saver, F. Vinuela.

St Luke's Hospital (7 cases): T. Grobelny, N. Ahktar, S. Arkin, I. Bettinger, C. Boutwell, M. Rymer, M. Schwartzman, C. Weinstein.

New York Presbyterian (Cornell and Columbia) (5 cases): J. Pile-Spellman, A. Segal, Y. P. Gobin, P. Meyers, S. Levine, S. Mangla, I. Ougorets, H. Reno, H. Riina, K. Scott.

Massachusetts General Hospital (1 case): J. Pryor, C. Ayata, N. Badjatia, F. Buonanno, L. Conrad, D. Greer, J. Hirsch, L. Hochberg, B. Hoh W. Koroshetz, R. Nogueira, J. Rabinov, G. Rordorf, J. Rosand, L. Schwamm, J. Sims, E. Smith.

UCSF Medical Center (1 case): R. Higashida, D. Bonovich, C. Dowd, J. Elkins, V. Halbach, S. Johnston, N. Ko, V. Singh, W. Smith.

Stanford University (0): M. Marks, G. Albers, H. Do, A. Hsia, D. Tong, C. Wijman.

Emory University (0): F. Tong, J. Dion, M. Frankel.

References

1. Katzan IL, Furlan AJ, Lloyd LE, Frank JI, Harper DL, Hinchey JA, Hammel JP, Qu A, Sila CA. Use of tissue-type plasminogen activator for acute ischemic stroke: the Cleveland area experience. *JAMA*. 2000;283:1151–1158.
2. Furlan AJ. Cva: Reducing the risk of a confused vascular analysis. *Stroke*. 2000;31:1451–1456.
3. Hacke W, Kaste M, Fieschi C, Toni D, Lesaffre E, Von Kummer R. For the ECASS study group. Intravenous thrombolysis with recombinant

- tissue plasminogen activator for acute hemispheric stroke: the European Cooperative Acute Stroke Study (ECASS). *JAMA*. 1995;274:1017–1025.
4. Hacke W, Kaste M, Fieschi C, Von Kummer R, Davalos A, Meier D. Randomised double-blind placebo-controlled trial of thrombolytic therapy with intravenous alteplase in acute ischaemic stroke (ECASS 2). *Lancet*. 1998;352:1245–1251.
 5. Clark WM, Wissman S, Albers GW, Jhamandas JH, Madden KP, Hamilton S. Recombinant tissue-type plasminogen activator (alteplase) for ischemic stroke 3 to 5 hours after symptom onset. The Atlantis study: a randomized controlled trial. *JAMA*. 1999;282:2019–2026.
 6. Clark WM, Albers GW, Madden KP, Hamilton S. The rtPA (alteplase) 0- to 6-hour acute stroke trial, part a. Results of a double-blind, placebo-controlled, multicenter study. *Stroke*. 2000;31:811–816.
 7. Furlan A, Higashida R, Wechsler L, Gent M, Rowley H, Kase C, Pessin M, Ahuja A, Callahan F, Clark W, Silver F, Rivera F. Intra-arterial pro-urokinase for acute ischemic stroke; the PROACT 2 study: a randomized controlled trial. *JAMA*. 1999;282:2003–2011.
 8. Welch K. Excision of occlusive lesions of the middle cerebral artery. *J Neurosurg*. 1956;13:73–80.
 9. Meyer FB, Piepgras DG, Sundt TJ, Yanagihara T. Emergency embolectomy for acute occlusion of the middle cerebral artery. *J Neurosurg*. 1985;62:639–647.
 10. Fogarty TJ, Cranley JJ, Krause RJ, Strasser ES, Hafner CD. A method for extraction for extraction of arterial emboli and thrombi. *Surg Gynecol Obst*. 1963;116:241.
 11. Davie JC, Richardson R. Distal internal carotid thrombo-embolism using a Fogarty catheter in total occlusion. *J Neurosurg*. 1967;27:171–177.
 12. Konig HJ, Krahling KH, Brandt M. Carotid-cavernous sinus fistula as a complication of embolectomy using a Fogarty catheter. *Neurosurg Rev*. 1981;4:191–192.
 13. Wikholm G. Mechanical intracranial embolectomy: A report of two cases. *Int Neuroradiol*. 1998;4:159–164.
 14. Wikholm G. Transarterial embolectomy in acute stroke. *Am J Neuro-Radiol*. 2003;24:892–894.
 15. Mayer TE, Hamann GF, Brueckmann HJ. Treatment of basilar artery embolism with a mechanical extraction device. Necessity of flow reversal. *Stroke*. 2002;33:2232–2235.
 16. Mahon BR, Nesbit GM, Barnwell SLWC, Marotta TR, Weill A, Teal PA, Qureshi AI. North American clinical experience with the EKOS MicroLysUS infusion catheter for the treatment of embolic stroke. *Am J Neuroradiol*. 2003;24:534–538.
 17. Eggers J, Koch B, Meyer K, Konig I, Seidel G. Effect of ultrasound on thrombolysis of middle cerebral artery occlusion. *Ann Neurol*. 2003;53:797–800.
 18. Leary MC, Saver JL, Gobin YP, Jahan R, Duckwiler GR, Vinuela F, Kidwell CS, Frazee J, Starkman S. Beyond tissue plasminogen activator: mechanical intervention in acute stroke. *Ann Emerg Med*. 2003;41:838–846.
 19. National Institute of Neurological Disorders and Stroke rt-PA Stroke Study Group. Tissue plasminogen activator for acute ischemic. *Stroke*. 1995;33:1581–1587.
 20. Lewandowski CA, Frankel M, Tomsick T, Broderick J, Frey J, Clark W, Starkman S, Grotta J, Spilker J, Khoury J, Brott T. Combined intravenous and intra-arterial rtPA versus intra-arterial therapy of acute ischemic stroke: Emergency Management of Stroke (EMS) bridging trial. *Stroke*. 1999;30:2598–2605.

Editorial Comment

A Mercy to Victims of Cerebrovascular Diseases

The year 2004 has been a year of reinforcing the idea of treating ischemic stroke. Measures for recanalization per endovascular approach are again proved to be feasible in the brain vessels. In this issue of *Stroke*, Gobin et al report an unprecedented, promising phase I feasibility study of removing clots from occluded vessels by corkscrew Mechanical Embolus Removal in Cerebral Ischemia (Merci) Retrieval System.¹ Treating ischemic stroke by embolectomy is not a new concept; however, until this year, the efficacy of the treatment is emerging and not too invasive.

Recently, the US Food and Drug Administration cleared the device for clot removing. Clot removing might be a reasonable way to treat the occluded brain vessels in practice, but the efficacy of treating acute ischemic stroke by this device is not yet unyielding; thus, the indication should be taken as pending approval. The requirements for approval of the efficacy might be as comparable to those applied to prourokinase from the Prolyse in Acute Cerebral Thromboembolism Trial (PROACT) II.²

Although IV recombinant tissue plasminogen activator has been available in many European and Asian countries since 2002, the short time window ruthlessly limited the treatment incidence. Prehospital delay has been more than enough.³ As shown in this study, limited to no patients had been treated in participating centers. Patients were additionally excluded if the arterial stenosis was proximal to the thrombus, in the opinion of the investigator. Either the

number of patients screened or the number of the angiograms done before the 30 eligible patients had been enrolled were not studied. These statistics will help to support the generalization and the feasibility of this technique. Until those figures are obtainable, this device might have the prospect to show efficacy in the real world outside the IV thrombolysis.

The clot removing might not be too invasive. The balloon inflation for the control of anterograde blood flow might reduce the flow-induced shear stress and potential fragmentation of the thrombus, but the duration and the vessels injury should be cautiously adjusted.

There were 6 successful recanalized intra-arterial procedures out of 8 patients among 14 patients with unsuccessful clot retrieval. This indicates that intra-arterial thrombolysis procedures, with the data granted by PROACT II, might help to back up the clots removing, left at the discretion of the interventionalist.

As in 2000, emergency cerebral angiography is out of the question in most hospitals. Thrombolysis In Myocardial Infarction (TIMI) grading is not a common language among stroke experts. There is a need for uniform definitions of collateral flow, degree of recanalization, assessment of perfusion, and infarct size to be applied in trials (such as phase 1 MERCI) to avoid confusing vascular analysis from the local principle investigators. Again, this is the time to take the great “technological leap” and

incorporate vascular testing into the routine assessment of acute ischemic stroke.⁴

Though not perfect, the noninvasive evaluation of patients with suspected intracranial artery stenosis or occlusion might be available soon.⁵ But the attempts of adapting these measures in acute stroke treatment have rarely been met. Future studies concerning avoidance of the negative cerebral angiograms are warranted, such as using MRI, computed tomographic angiograms, or transcranial Doppler in the screening phase. Although the National Institutes of Health Stroke Scale could serve as a useful tool, the evidence to prove the occlusion in order to initiate the invasive treatment is crucial.

Although the desmoteplase thrombolysis selected by MRI perfusion/diffusion mismatch and intracranial stenting⁶ showed potential in 2004, the expenditure of these great technological leaps is sobering. The cost of the treatment in the few hours after stroke might be more than the amount for whole short-term hospitalization in certain welfare areas.⁷ Although with the benefits, the phase 2 MERCI study with 141 patients will struggle to support the use of this device outside the current participating centers. The estimates of effectiveness and cost-effectiveness of the device would be difficult or imprecise but desirable. With the estimates at hand and affirmative, the device would be really a mercy to victims of cerebrovascular diseases.

Ku-Chou Chang, MD, *Guest Editor*
Assistant Professor of Neurology
First Department of Neurology
Chang Gung Memorial Hospital
Kaohsiung, Taiwan

References

1. Gobin YP, Starkman S, Duckwiler GR, Grobelny T, Kidwell CS, Jahan R, Pile-Spellman J, Segal A, Vinuela F, Saver JL. MERCI 1: a phase 1 study of mechanical embolus removal in cerebral ischemia. *Stroke*. 2004; 35:2848–2854.
2. Furlan AJ, Higashida R, Wechsler L, Gent M, Rowley H, Kase C, Pessin M, Ahuja A, Callahan F, Clark WM, Silver F, Rivera F, for the PROACT Investigators. Intra-arterial prourokinase for acute ischemic stroke: the PROACT II study: a randomized controlled trial. *JAMA*. 1999;282:2003–2011.
3. Chang KC, Tseng MC, Tan TY. Prehospital delay after acute stroke in Kaohsiung, Taiwan. *Stroke*. 2004;35:700–704.
4. Furlan AJ. CVA: reducing the risk of a confused vascular analysis. The Feinberg Lecture. *Stroke*. 2000;31:1451–1456.
5. Stroke Outcomes and Neuroimaging of Intracranial Atherosclerosis (SONIA) Trial Investigators. Stroke Outcome and Neuroimaging of Intracranial Atherosclerosis (SONIA): design of a prospective, multicenter trial of diagnostic tests. *Neuroepidemiology*. 2004;23: 23–32.
6. Jiang WJ, Wang YJ, Du B, Wang SX, Wang GH, Jin M, Dai JP. Stenting of symptomatic M1 stenosis of middle cerebral artery: an initial experience of 40 patients. *Stroke*. 2004;35:1375–1380.
7. Chang KC, Tseng MC. Costs of acute care of first-ever ischemic stroke in Taiwan. *Stroke*. 2003;34:e219–e221.