

# Stroke

American Stroke  
Association<sup>SM</sup>

A Division of American  
Heart Association



JOURNAL OF THE AMERICAN HEART ASSOCIATION

## **Editorial Comment--Mechanical Embolus Removal: A New Day Dawning**

Thomas A. Tomsick

*Stroke* 2005;36;1439-1440

Stroke is published by the American Heart Association, 7272 Greenville Avenue, Dallas, TX 75214  
Copyright © 2005 American Heart Association. All rights reserved. Print ISSN: 0039-2499. Online  
ISSN: 1524-4628

The online version of this article, along with updated information and services, is  
located on the World Wide Web at:

<http://stroke.ahajournals.org/cgi/content/full/36/7/1439>

Subscriptions: Information about subscribing to Stroke is online at  
<http://stroke.ahajournals.org/subscriptions/>

Permissions: Permissions & Rights Desk, Lippincott Williams & Wilkins, 351 West Camden  
Street, Baltimore, MD 21202-2436. Phone 410-5280-4050. Fax: 410-528-8550. Email:  
[journalpermissions@lww.com](mailto:journalpermissions@lww.com)

Reprints: Information about reprints can be found online at  
<http://www.lww.com/static/html/reprints.html>

# Safety and Efficacy of Mechanical Embolectomy in Acute Ischemic Stroke

## Results of the MERCI Trial

Wade S. Smith, MD, PhD; Gene Sung, MD; Sidney Starkman, MD; Jeffrey L. Saver, MD; Chelsea S. Kidwell, MD; Y. Pierre Gobin, MD; Helmi L. Lutsep, MD; Gary M. Nesbit, MD; Thomas Grobelny, MD; Marilyn M. Rymer, MD; Isaac E. Silverman, MD; Randall T. Higashida, MD; Ronald F. Budzik, MD; Michael P. Marks, MD; for the MERCI Trial Investigators

**Background and Purpose**—The only Food and Drug Administration (FDA)-approved treatment for acute ischemic stroke is tissue plasminogen activator (tPA) given intravenously within 3 hours of symptom onset. An alternative strategy for opening intracranial vessels during stroke is mechanical embolectomy, especially for patients ineligible for intravenous tPA.

**Methods**—We investigated the safety and efficacy of a novel embolectomy device (Merci Retriever) to open occluded intracranial large vessels within 8 hours of the onset of stroke symptoms in a prospective, nonrandomized, multicenter trial. All patients were ineligible for intravenous tPA. Primary outcomes were recanalization and safety, and secondary outcomes were neurological outcome at 90 days in recanalized versus nonrecanalized patients.

**Results**—Recanalization was achieved in 46% (69/151) of patients on intention to treat analysis, and in 48% (68/141) of patients in whom the device was deployed. This rate is significantly higher than that expected using an historical control of 18% ( $P<0.0001$ ). Clinically significant procedural complications occurred in 10 of 141 (7.1%) patients. Symptomatic intracranial hemorrhages was observed in 11 of 141 (7.8%) patients. Good neurological outcomes (modified Rankin score  $\leq 2$ ) were more frequent at 90 days in patients with successful recanalization compared with patients with unsuccessful recanalization (46% versus 10%; relative risk [RR], 4.4; 95% CI, 2.1 to 9.3;  $P<0.0001$ ), and mortality was less (32% versus 54%; RR, 0.59; 95% CI, 0.39 to 0.89;  $P=0.01$ ).

**Conclusions**—A novel endovascular embolectomy device can significantly restore vascular patency during acute ischemic stroke within 8 hours of stroke symptom onset and provides an alternative intervention for patients who are otherwise ineligible for thrombolytics. (*Stroke*. 2005;36:1432-1440.)

**Key Words:** angiography ■ embolism ■ embolectomy ■ ischemia ■ reperfusion ■ stroke, acute ■ thrombectomy ■ treatment outcome

Approximately 750 000 strokes occur in the United States annually, of which 85% are ischemic. Ischemic stroke may be caused by occlusion of large ( $>2$  mm) intracranial arteries, and large-vessel occlusions carry a particularly high mortality estimated between 53% and 92%.<sup>1-4</sup> Reopening large cerebral vessels would be expected to reduce neurological morbidity and mortality if performed before ischemic brain injury is maximal. Although improved neurological outcome has been demonstrated for patients treated with thrombolytic drugs administered intravenously<sup>5</sup> and via catheter,<sup>6</sup> many patients are ineligible for thrombolytic therapy. A mechanical embolectomy device could be an alternative

### See Editorial Comment, pg 1439

stroke therapy, especially for patients ineligible to receive thrombolytic agents. The MERCI (Mechanical Embolus Removal in Cerebral Ischemia) trial tested the safety and efficacy of an endovascular device to restore patency of occluded intracranial vessels within the first 8 hours of acute ischemic stroke.

### Materials and Methods

The MERCI trial was conducted in 2 parts. Part I enrolled 55 patients and part II enrolled an additional 96 patients, for a total of 151

Received April 6, 2005; accepted April 28, 2005.

From University of California, San Francisco, Department of Neurology (W.S.S.), San Francisco, Calif; the Department of Neurology (G.S.), University of Southern California, Los Angeles; the Department of Neurology (S.S., J.L.S.) and the Department of Emergency Medicine (S.S.), University of California, Los Angeles; the Division of Interventional Neuroradiology (Y.P.G.), Weill Cornell Medical College, New York, NY; Oregon Health Science University (H.L.L., G.M.N.), Portland; Saint Luke's Hospital (T.G., M.M.R.), Kansas City, Mo; Hartford Hospital (I.E.S.), Hartford, Conn; Department of Radiology (R.T.H.), University of California, San Francisco; Riverside Methodist Hospital (R.F.B.), Columbus, Ohio; and the Department of Radiology (M.P.M.), Stanford University, Palo Alto, Calif.

Correspondence to Wade S. Smith, MD, PhD, University of California, San Francisco, Department of Neurology, 505 Parnassus Avenue, San Francisco, CA 94143-0114. E-mail smithw@neurology.ucsf.edu

© 2005 American Heart Association, Inc.

Stroke is available at <http://www.strokeaha.org>

DOI: 10.1161/01.STR.0000171066.25248.1d

patients. Part II had an expanded eligibility and longer follow-up than part I as detailed. The results of both parts are combined for the purpose of reporting overall safety and efficacy of the procedure; preliminary results for the first 30 treated patients appear elsewhere.<sup>7</sup>

### Study Design and Hypothesis

MERCI was a prospective, single-arm, multicenter trial conducted at 25 United States centers. The study tested whether a mechanical embolectomy device could safely restore vascular patency at a rate exceeding a prespecified rate of spontaneous recanalization in patients presenting within 8 hours of onset of an acute ischemic stroke. The trial design was approved by the Food and Drug Administration (FDA) under an Investigational Device Exemption and by the respective institutional review boards of each study site. Waiver of informed consent was approved by FDA and invoked at 2 study sites for patients who were unable to consent for themselves and for whom no surrogate was available. The study was overseen by an independent data safety monitoring board.

### Patient Selection

Patients were eligible who met all of the following criteria: age 18 years or older, signs and symptoms of acute stroke, National Institutes of Health Stroke Scale (NIHSS) score  $\geq 8$ , a CT scan of the brain excluding hemorrhage, and stroke symptom duration between 3 and 8 hours, or duration between 0 and 3 hours and a contraindication for intravenous tissue plasminogen activator (tPA). After cerebral angiography, eligible patients had to have occlusion of a treatable vessel. Treatable vessels were defined as the intracranial vertebral artery, basilar artery, intracranial carotid artery (ICA), ICA terminal bifurcation, or the middle cerebral artery (MCA) first division (M1). Part II allowed patients with occlusion of the secondary division of the MCA (M2). The patient was defined as enrolled once the balloon guide catheter was placed in the vasculature.

Patients were ineligible for the study if any of the following were true: informed consent was not obtained (and approval for waiver of explicit consent for emergency circumstances had not been obtained at the study site), current pregnancy, serum glucose  $< 50$  mg/dL, excessive tortuosity of cervical vessels precluding device delivery/deployment, known hemorrhagic diathesis, known coagulation factor deficiency, oral anticoagulation treatment with international normalized ratio (INR)  $> 1.7$  in part I and  $> 3.0$  in part II, use of heparin within 48 hours, and a partial thromboplastin time (PTT)  $> 2$ -times normal, platelet count  $< 50\,000/\mu\text{L}$  ( $< 30\,000/\mu\text{L}$  in part II), history of severe allergy to contrast media, sustained systolic blood pressure  $> 185$  mm Hg or diastolic blood pressure  $> 110$  mm Hg despite treatment, CT scan revealing significant mass effect with midline shift or greater than one-third of the MCA region with hypodensity (sulcal effacement and/or loss of gray-white differentiation alone was allowed),  $> 50\%$  stenosis of the artery proximal to the target vessel, or life expectancy  $< 3$  months.

### Embolectomy Procedure

All patients underwent conventional cerebral angiography. Investigators were instructed to perform 4-vessel cerebral angiography before determining eligibility for the trial. After enrollment, patients were given intravenous heparin (3000 U bolus in part I, no bolus specified in part II) during the procedure. The Merci Retrieval System (Concentric Medical, Inc) was tested under an approved FDA protocol. A description of the embolectomy procedure can be found elsewhere.<sup>7</sup> Up to 6 passes with the device were allowed. If flow was restored with 6 or fewer passes of the device, successful recanalization was attributed to the device. Successful revascularization was defined as achieving Thrombolysis In Myocardial Infarction<sup>8</sup> (TIMI) II or III flow in all treatable vessels. Successful recanalization for the MCA required both M1 and M2 branches to be at least TIMI II; for ICA terminal lesions, the ICA, M1, and M2 branches needed to be at least TIMI II, and for the vertebral artery, both the vertebral and basilar arteries needed to be at least TIMI II to be considered recanalized. TIMI scoring of angiography was

scored by the individual site investigator who was not blinded to clinical outcome. The status of arterial branches distal to the treatable vessel was not considered when ascribing the TIMI score. If the treatable vessel was not opened to at least TIMI II flow with a maximum of 6 passes with the device, it was considered a treatment failure for the device. Intra-arterial thrombolytics were allowed in cases of treatment failure with the device, or to treat distal embolus not accessible to the device after successful proximal embolectomy. Intravenous heparin after the procedure was allowed at the discretion of the investigator.

### Clinical Variables and Measurement of Outcome

Patient demographics, medical history, vital signs, and routine laboratory values were documented on standardized clinical report forms. In part I, the NIHSS and modified Rankin Scale (mRS) scores were obtained at baseline and 30 days. In part II, patients had additional NIHSS and mRS assessments for up to 90 days. CT brain imaging was performed at 24 hours and at any time that there was a decline in patient neurological status. Symptomatic intracranial hemorrhage was defined as a decline of 4 or more points in the NIHSS score within 24 hours with any blood products identified on head CT scan (petechial bleeding, hematoma, or subarachnoid hemorrhage), any intracranial hemorrhage in which no further NIHSS scores were available beyond baseline and the patient died, or any subarachnoid hemorrhage. All 24-hour CT scans were reviewed in a core laboratory and all hemorrhages were adjudicated by the data safety monitoring board. An asymptomatic hemorrhage was defined as any nonsubarachnoid blood on the 24-hour CT or MR scan with no more than a 3-point decline in the NIHSS score.

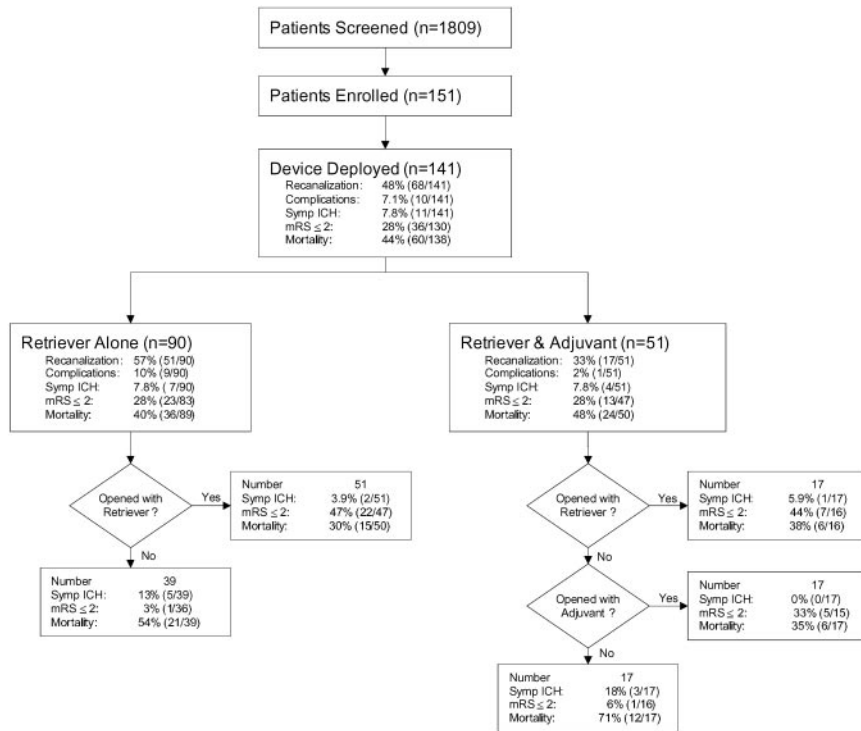
Primary outcomes were the rate of vascular recanalization and the observed rate of device-related complications. Recanalization was defined as (TIMI) grades II and III flow assessed immediately after treatment with the device. The benchmark for spontaneous recanalization was chosen as 18%, which was the spontaneous recanalization rate 2 hours after initial angiography reported in the control arm of the PROACT-II study.<sup>6</sup> Device-related complications were defined as vascular perforation, intramural arterial dissection, or embolization of a previously uninvolved territory. Procedure-related complications were defined as any device-related complications plus any other complications judged related to the procedure. Clinically significant procedure complications were defined as a procedure complication with decline in NIHSS of  $\geq 4$ , any subarachnoid hemorrhage, or groin complication requiring surgery or blood transfusion. Secondary outcomes included clinical outcome, as measured by the mRS and NIHSS scores at 30 and 90 days, and the combined events of death, myocardial infarction, and second stroke within 30 days. Good neurological outcome was defined as mRS  $\leq 2$ , or NIHSS score improvement of 10 points or more.

### Statistical Analysis

Primary outcomes are reported based on intention-to-treat analysis; all other analysis is reported for those patients who had the embolectomy device deployed. Each clinical and demographic variable was tested as predictors of good neurological outcome and mortality with Fisher exact test. These variables included baseline NIHSS score, age, gender, race, blood pressure, temperature, glucose, medical history (coronary disease, atrial fibrillation, congestive heart failure, diabetes mellitus, hyperlipidemia, smoking, previous stroke or transient ischemic attack, or endarterectomy), latency to treatment, site of vascular occlusion, revascularization, number of attempts to remove clot, duration of procedure, and use of tPA as adjuvant treatment. Logistical regression of good outcome included all variables with  $P < 0.20$  from the univariate analysis, then eliminated variables in a forward and backward scheme to arrive at the best model. In case of death, Rankin scores were set to 6 and NIHSS score were set to 42. All analyses were performed using SAS for Windows, version 8.2.

### Results

During the study period of May 2001 and December 2003, 1809 patients were screened, and 151 patients were enrolled



**Figure 1.** Patient flow diagram. Ten enrolled patients did not have the embolectomy device deployed for reasons explained in the text. MRS indicates modified Rankin scale; symp ICH, symptomatic intracranial hemorrhage.

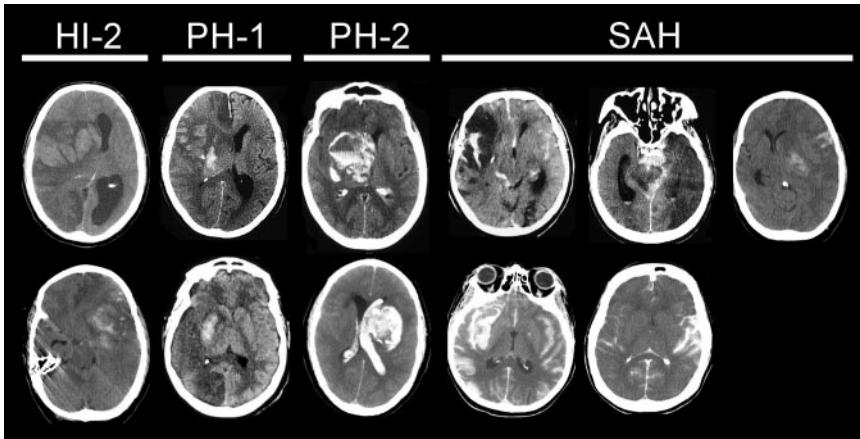
in the trial (Figure 1). Chief exclusions to screened patients included NIHSS score too low or rapidly improving symptoms, intracranial hemorrhage, or inability to obtain consent. Of the 151 enrolled patients, 10 patients did not have the embolectomy device deployed for the following reasons: spontaneous recanalization of the vessel (n=1), occlusion of an ineligible vessel (n=1), patient presented outside the 8-hour time window (n=1), excessive cervical artery stenosis (n=1), excessive tortuosity (n=2), thrombus judged too large for the embolectomy device (n=1), inability to access the thrombus with a microcatheter (n=2), and inability to advance the embolectomy device through the microcatheter (n=1). Because the study was designed to investigate the performance characteristics of the embolectomy device, these 10 patients were not followed-up beyond hospital discharge but are included in the intention-to-treat analysis. Of the 141 patients who had the device deployed, 2 patients withdrew consent for follow-up after hospital discharge. One additional patient was lost to follow-up between 30 and 90 days. Baseline and postembolectomy angiography was available for 141 patients, and 90-day mortality was available for 138 patients. Neurological follow-up at 30 days was more complete than at 90 days because part I of the study specified a 30-day follow-up.

Patient demographics and primary outcomes are shown in Table 1. Recanalization (TIMI II/III) of treatable vessels with the embolectomy device was achieved in 69 of 151 (46%) patients on intention-to-treat basis, which is significantly greater than the expected spontaneous recanalization rate found in PROACT-II<sup>6</sup> of 18% ( $P < 0.0001$ , exact binomial test). Considering the 141 patients who actually had the device deployed, 68 of 141 (48%,  $P < 0.0001$ ) patients were recanalized with the device. Postprocedure TIMI scores of

treatable vessels were TIMI III (n, %: 34, 24%), TIMI II (34, 24%), TIMI I (26, 18%), and TIMI 0 (47, 33%). In 51 instances, investigators used adjuvant therapy after deployment of the embolectomy device (Figure 1). In 17 cases the occluded artery was opened with the device and intra-arterial tPA was infused into distal vascular branches not accessible by the device. In 17 other instances, the device failed to open the target vessel and adjuvant thrombolytics (n=14) or angioplasty/snare (n=3) achieved recanalization; these 17 cases were not counted as successfully recanalized by the

**TABLE 1. Patient Demographics, Baseline Stroke Score, Site of Vascular Occlusion, and Primary Outcomes**

Age, mean ± SD, y	67.0 ± 15.5
Female, %	46
Baseline NIHSS, mean ± SD	20.1 ± 6.6
Site of vascular occlusion, %	
ICA	19
ICA terminal bifurcation	14
Middle cerebral artery	57
Vertebral artery	1
Basilar artery	9
Revascularization (%; 95% CI)	48 (40–57)
Procedural complications (%; 95% CI)	
All	13 (7.3–18)
Clinically significant	7.1 (2.9–11)
Symptom onset to groin puncture, mean hr ± SD	4.3 ± 1.7
Procedure duration, mean hr ± SD, (range)	2.1 ± 1.0 (0.3–5.9)
Attempts to remove clot (n ± SD)	2.9 ± 1.5
Enrolled < 3 hours of symptom onset, no. (%)	38 (27)



**Figure 2.** Symptomatic intracranial hemorrhages categorized by hemorrhage type.<sup>10</sup>

embolectomy device. Thirty-eight (27%) enrolled patients presented within 3 hours of stroke symptom onset but had contraindication for intravenous tPA. The top 3 contraindications were recent surgery/trauma, decline of consent for tPA, and current oral anticoagulation therapy.

Procedural complications occurred in 18 of 141 (13%) patients, and in 10 of 141 (7.1%) these were clinically significant. Three cases of embolization of a previously uninvolved vascular territory occurred (all anterior cerebral artery [ACA] after MCA embolectomy), and one of these was clinically significant. Vascular dissection occurred in 4 patients but led to no immediate clinical consequence. However, 1 of these 4 patients died from a gastrointestinal hemorrhage at 30 days while taking warfarin sodium and was therefore considered clinically significant. Six cases of intracranial vascular perforation were observed during angiography, leading to 2 patients having subarachnoid hemorrhage. Three of these 6 complications were considered clinically significant. An additional 3 cases of subarachnoid hemorrhage were observed without documented vascular perforation and were considered clinically significant. Finally, 3 patients had clinically significant groin hemorrhages requiring surgical repair or blood transfusion.

Symptomatic intracranial hemorrhages occurred in 11 of 141 (7.8%) patients. Five of the 11 patients had subarachnoid hemorrhage, and 6 patients had intraparenchymal hemorrhages. Of these 6 intraparenchymal hemorrhage patients, 2 were large hematomas with mass effect (parenchymal hematoma type 2).<sup>10</sup> Symptomatic intracranial hemorrhages (Figure 2) occurred with equal frequency in patients who were treated with the device alone and in those who received adjuvant therapy. Asymptomatic hemorrhages occurred in 39 of 141 (27.7%) patients; none of these hemorrhages was subarachnoid or parenchymal hematoma type 2.

Of the 341 embolectomy devices used during the trial, 11 devices fractured. In 2 patients the device fracture likely contributed to the patient’s death. Interviews with the investigators indicated that the majority of fractures occurred from over-torquing the device. The training program and instructions for use were revised and design modifications were made to increase the strength of the device.

Univariate predictors of good neurological outcome are shown in Table I (available online only at <http://www.strokeaha.org>). In summary, 7 variables predicted a 90-day mRS of 2 or less, including lower baseline NIHSS score, younger age, revascularization success, fewer attempts to

**TABLE 2. Neurological Outcomes at 30 and 90 days**

Assessment	Percentage with Outcome			Relative Risk (95% CI)	P Value‡
	Overall	Recanalized	Not Recanalized		
Favorable outcome, 30 d					
Modified Rankin score*	22.6	36.4	9.9	3.69 (1.70–7.98)	0.0002
NIHSS score†	34.1	54.0	15.9	3.39 (1.88–6.09)	<0.0001
Favorable outcome, 90 d					
Modified Rankin score*	27.7	46.0	10.4	4.41 (2.08–9.33)	<0.0001
NIHSS score†	32.4	50.0	17.5	2.85 (1.52–5.35)	0.0007
Mortality at 30 days	37.1	23.9	49.3	0.48 (0.30–0.79)	0.0028
Mortality at 90 days	43.5	31.8	54.2	0.59 (0.39–0.89)	0.0101
Death, MI, new stroke, 30 d	40.0	29.9	49.3	0.61 (0.39–0.93)	0.0247

\*Rankin ≤2.

†NIHSS score improvement from baseline by ≥10 points.

‡P value is for ad-hoc testing of the difference in outcome rates between the recanalized and not recanalized groups using a 2-tailed Fisher’s exact test.

**TABLE 3. NIHSS, Recanalization and Outcomes by Site of Vascular Occlusion**

	Site of Occlusion		
	Posterior n=14	Internal Carotid n=47	Middle Cerebral n=80
Baseline NIHSS, mean±SD	27±11	19±4	20±6
Revascularization, %	50	53	45
Favorable outcome, 90 d, %			
Modified Rankin score	36	24	29
NIHSS score	50	33	29
Mortality, 90 d, %	43	51	39
Symptomatic Hemorrhage, %	7	15	4

remove clot, shorter procedure duration, absence of hypertension, and left-side hemispheric ischemia. Neurological outcomes of patients were more favorable and mortality lower in patients who had successful recanalization with the device (Table 2). Time from stroke symptom onset to treatment was not associated with neurological outcome. Neurological outcome did not differ by treatment vessel as shown in Table 3.

Independent predictors of outcome were identified by multivariate modeling. Revascularization was independently associated with good neurological outcome (mRS  $\leq 2$ ) using multivariate logistic regression (Table 4). Alternately, the absence of recanalization was independently associated with mortality. No clinical or demographic variable was associated with successful revascularization in univariate or multivariate analysis.

### Discussion

Rapid restoration of cerebral blood flow is the principle goal of ischemic stroke therapy. The tissue plasminogen activator (tPA) is effective in treating acute ischemic stroke if given intravenously to patients within 3 hours of stroke symptom onset.<sup>5</sup> Intra-arterial thrombolysis extends this time window for patients with MCA occlusions out to 6 hours,<sup>6</sup> and may be combined with intravenous tPA.<sup>9</sup> However, many people are ineligible for intravenous thrombolytic therapy, as were all patients in this trial, either because of time constraints or because of specific contraindication to the drug, and there is no FDA-approved drug for intra-arterial delivery.

The MERCI trial provides data on the safety and effectiveness of endovascular embolectomy in acute ischemic stroke.

Successful revascularization was achieved in 46% of patients on intention-to-treat analysis, and in 48% of patients in which the device was deployed. This is significantly greater than the 18% spontaneous recanalization rate of the middle cerebral artery reported in the PROACT-II study,<sup>6</sup> confirming that the device restores blood flow. Mechanical embolectomy offers an intervention to patients who are otherwise ineligible for thrombolytics and extends the time window up to 8 hours.

Recanalization was achieved within all major cerebral vessels. Occlusion of the intracranial ICA, ICA terminal bifurcation, and vertebrobasilar arteries typically involves a high clot burden that is difficult to dissolve with thrombolytics alone so embolectomy may offer a better means to open these vascular segments.<sup>1,11,12</sup> Compared with other vascular segments studied here, however, the revascularization rate was lowest in the MCA. The 45% recanalization of the MCA in the MERCI trial is less than the 66% rate reported with intra-arterial prourokinase.<sup>6</sup> No demographic or clinical variables were associated with failure to achieve revascularization, indicating that there is no justification at present to narrow the entry criteria used in the MERCI study in determining patients who may be selected for the procedure. Seventeen patients whose vessels were not opened with the embolectomy device (and were not counted as an embolectomy success) were later opened with thrombolytic treatment or other mechanical means. Deciding how best to use thrombolytics in combination with the device will require further investigation.

Symptomatic intracranial bleeding occurred in 11 patients. Five of the 11 hemorrhages were subarachnoid and were likely related to vascular perforation. Of the 6 patients with parenchymal blood, only 2 had a hemorrhage large enough to contribute to neurological decline.<sup>10</sup> Therefore, for the purposes of comparison with other trials, the MERCI symptomatic intracranial hemorrhage rate is best estimated at 7 of 141 (5%). This is higher than the rates of intracranial hemorrhage in the placebo arms of the NINDS intravenous tPA trial<sup>5</sup> (0.6%) and the placebo arm of the intra-arterial pro-urokinase trial PROACT-II<sup>6</sup> (2%). However, the MERCI hemorrhage rate is numerically less than the rates of hemorrhage from intravenous tPA (6% in NINDS study<sup>5</sup>), from combined intravenous/intra-arterial tPA (6% in the IMS trial<sup>9</sup>), and from intra-arterial prourokinase (10% in PROACT-II<sup>6</sup>). As a conservative comparison with PROACT-II, the rate of all symptomatic hemorrhages (petechial, hematoma, and subarachnoid) in the MERCI MCA subgroup was 6%. Therefore,

**TABLE 4. Multivariate Predictors of Good Outcome and Mortality**

Variable	mRS $\geq 2$		Mortality	
	Odds Ratio (95% CI)	P Value	Odds Ratio (95% CI)	P Value
Revascularization	12.82 (2.95–55.75)	<0.0001	0.33 (0.14–0.77)	0.0098
Age, y, decade	0.94 (0.90–0.98)	0.0009	1.06 (1.03–1.09)	0.0012
Baseline NIHSS	0.78 (0.67–0.89)	0.0007	1.09 (1.01–1.16)	0.0156
Procedure time, hr	0.36 (0.17–0.78)	0.0077	...	...
Right brain infarct	0.14 (0.04–0.52)	0.0041	...	...

the rates of symptomatic intracranial bleeding with embolectomy do not exceed and may be smaller than those from existing treatments for acute ischemic stroke.

Clinically significant procedural complications occurred in 10 of 141 (7.1%) MERCI patients. This risk compares similarly to the 6% to 8.8% risk of significant intracranial hemorrhage for intravenous-tPA<sup>5,13,14</sup> and 10% hemorrhage risk of intra-arterial prourokinase.<sup>6</sup> The vascular perforation rate seen in MERCI was 4.3%, which is similar to 3.8% seen in the IMS study,<sup>9</sup> and 2.9% using endovascular photoacoustic recanalization.<sup>12</sup> Clinically significant groin complications occurred in 2.1% of MERCI patients compared with 3.8% in the IMS study.<sup>9</sup> Overall, patients treated with mechanical embolectomy face a comparable risk of complication compared with intravenous, intra-arterial, and intravenous combined with intra-arterial thrombolytics.

Overall mortality in the MERCI trial was 44%, which is greater than most prospective trials of acute stroke. Patients selected for MERCI had severe strokes with large vessel intracranial occlusions, and these characteristics are strongly associated with mortality.<sup>1-4,15</sup> The MERCI median baseline NIHSS of 19 is the highest of any angiographic-based trial, exceeding that of PROACT-II<sup>6</sup> (NIHSS=17) and IMS<sup>9</sup> (NIHSS=18). Additionally, 9% of MERCI patients had basilar occlusions, which are associated with 83% to 92% mortality if the vessel fails to open with intra-arterial thrombolytic therapy.<sup>2,3</sup> Fourteen percent of MERCI patients had occlusions of the terminal ICA bifurcation, which carries a mortality risk of 57% after failed intravenous or intra-arterial thrombolysis.<sup>1</sup> The majority of MERCI patients had MCA distribution strokes, a stroke subtype that carries a 27% to 78% mortality rate if untreated.<sup>4,6</sup> Compared with the PROACT-II trial that reported a 27% (95% CI, 16% to 38%) mortality rate in the control arm, MERCI patients were 3 years older and had higher NIHSS scores by 3 points. Age and NIHSS are 2 of the most important prognostic factors for mortality as was found in multivariate analysis in this study and elsewhere,<sup>15</sup> suggesting that the greater mortality observed in MERCI compared with PROACT II is related to these differences in study population. Specifically, the mortality for PROACT-II eligible MERCI patients (MCA, age 85 or younger, NIHSS  $\leq$ 30) was 33% (95% CI, 23% to 46%), which is not significantly different than PROACT-II control patients, suggesting that usage of the device is safe. Therefore, the mortality reported in this trial likely reflects stroke severity, but specific comparison with a concurrent control group would be necessary to confirm this.

Multivariate logistical regression analysis showed that revascularization was an independent predictor of neurological outcome and mortality, suggesting a treatment effect of the device. Other investigators have reported similar findings using thrombolytics in case series.<sup>2,9,16-19</sup> These results support the pathophysiological assumption that restoration of blood flow improves outcome. However, definitive conclusion of clinical efficacy in treating ischemic stroke will require a control group comparison. The only FDA-approved drug for acute stroke is intravenous tPA within 3 hours of stroke symptom onset. Based on the MERCI trial results, the FDA cleared the MERCI Retriever in 2004 for restoring

blood flow in patients experiencing an acute stroke who are otherwise ineligible for intravenous tPA, or in whom intravenous tPA treatment has failed. Mechanical embolectomy offers an intervention to patients up to 8 hours after onset who are otherwise ineligible for thrombolytics.

## Appendix

### MERCI Trial Investigators

#### Investigators

*National Principal Investigator:* Wade S. Smith, MD, PhD, University of California, San Francisco

*Data Safety Monitoring Board: Chair:* Gene Sung, MD, University of Southern California; *Biostatistician:* Phil Hormel, MS; *Members:* Tim W. Malisch, MD, University of Illinois at Chicago; Steven L. Giannotta, MD, University of Southern California; Steven Rudolph, MD, Lenox Hill Hospital, Fady T. Charbel, MD, University of Illinois at Chicago

*Imaging Core Lab:* Paul Kim, MD, University of Southern California

*Writing Committee:* Ronald Budzik, MD; Y. Pierre Gobin, MD; Thomas Grobelny, MD; Randall T. Higashida, MD; Chelsea Kidwell, MD; Helmi L. Lutsep, MD; Michael Marks, MD; Gary Nesbit, MD; Marilyn M. Rymer, MD; Jeffrey Saver, MD; Isaac E. Silverman, MD; Wade S. Smith, MD; Sidney Starkman, MD; Gene Sung, MD

*Site Principal Investigator (PI), Co-investigators, and Study Coordinators in order of enrollment (N):* **University of California at Los Angeles Medical Center:** (22) PI: Sidney Starkman, MD; Gary Duckwiler, MD; Megan Leary, MD; Chelsea Kidwell, MD; Jeffrey Saver, MD; Fernando Vinuela, MD; Reza Jahan, MD; Y. Pierre Gobin, MD; Judy Guzy, RN. **Oregon Health Science University:** (22) PI: Helmi Lutsep, MD; Stanley Barnwell, MD; Wayne Clark, MD; Ted Lowenkopf, MD; Elizabeth North, MD; Joseph Quinn, MD; Robert Egan, MD; Todd Kuether, MD; John Roll, MD; George Luh, MD; Gary Nesbit, MD; Barbara Dugan, RN. **Saint Luke's Hospital:** (21) PI: Thomas Grobelny, MD; Naveed Akhtar, MD; Steven Arkin, MD; Irene Bettinger, MD; Marilyn Rymer, MD; Charles Weinstein, MD; Michael Schwartzman, MD; Christine Boutwell, MD; Barbara Gruenfelder, RN. **Massachusetts General Hospital:** (11) PI: Walter Korosetz, MD; Johnny Pryor, MD; Neeraj Badjatia, MD; Ferdinando Buonarmo, MD; Lawrence Conrad, MD; David Greer, MD; Raul Nogueira, MD; James Rabinov, MD; Guy Rordorf, MD; Jonathan Rosand, MD; Lee Schwamm, MD; John Sims, MD; Eric Smith, MD; Brian Hoh, MD; Joshua Hirsch, MD; Cenk Ayata, MD; Leigh Hochberg, MD; Joanie Cacciola, RN. **NY Presbyterian Hospital-Columbia:** (11) PI: John Pile-Spellman, MD; Sean Lavine, MD; Sundeep Mangla, MD; Philip Meyers, MD; Leslie Schmidt, NP

**The Stroke Center at Hartford Hospital:** (11) PI: Isaac Silverman, MD; Stephen Ohki, MD; Gary Speigel, MD; Martha Alquist, LPN, CCRP; Dawn Beland, MSN. **NY Presbyterian Hospital-Cornell:** (6) PI: Alan Segal, MD; Ai-His Liu, MD; Igor Ougrets, MD; Howard Riina, MD; Y. Pierre Gobin, MD; Kimberly Salvaggio, NP. **University of California at San Francisco Medical Center:** (6) PI: Randall Higashida, MD; Christopher Dowd, MD; Van Halbach, MD; Vineeta Singh, MD; Nerissa Ko, MD; Jacob Elkins, MD; S. Claiborne Johnston, MD, PhD; J. Claude Hemphill, MD, MSc; David C. Bonovich, MD; Sharon Filler, RN; Melissa Meighan, RN. **Florida Hospital Neuroscience Institute:** (5) PI: Frank Huang-Hellinger, MD; Susan Mitchell, RN. **Riverside Methodist Hospital:** (5) PI: Ronald Budzik, MD; Geoffrey Eubank, MD; Erik Arce, MD; Jim Fulop, MD; John Lippert, MD; Tom Davis, MD; J. Kevin McGraw, MD; Peter Pema, MD; Paula Meyers, RN. **Stanford University Medical Center:** (5) PI: Michael Marks, MD; Huy Do, MD; Gregory Albers, MD; Amie Hsia, MD; David Tong, MD; Christine Wijamm, MD; Mary Marcellus, RN. **Carolina Neurosurgery and Spine:** (4) PI: Joseph Bernard, MD; Gary DeFilipp, MD; Richard Bellon, MD; Barry McGinnis, MD; Andrea Dietrich, MD; Steve Putnam, MD; Peggy Boltes, RN. **Georgetown University:** (2)

PI: Vance Watson, MD; John DeSimone, MD; Manual Yepes, MD; Theresa Kowal, RN. **University of Maryland:** (2) PI: Joanne Stallmeyer, MD; Abraham Obuchowski, MD; Greg Zoarski, MD; Marian LaMonte, MD; Marcella Wozniack, MD; Deborah Schofield, RN. **University of Pennsylvania:** (2) PI: David Liebeskind, MD; Scott Kasner, MD; Brett Cucchiara, MD; Steven Messe, MD; Robert Taylor, MD; Michael McGarvey, MD; Robert Hurst, MD; Linda Bagley, MD; John Weigele, MD; Jessica Clarke, RN, BSN. **Brigham and Women's Hospital:** (1) PI: Walter Koroshetz, MD; Kai Frerichs, MD; Steven Feske, MD; Alexander Norbash, MD; Galen Hendersen, MD; Farzanah Sorond, MD; John Baker, MD; Peng Chen, MD; Joanne O'Hara, RN. **Latter-Day Saints Hospital:** (1) PI: John Jacobs, MD; Lisa Yananse, MD; Duane Blatter, MD; Albert Lee Bahr, MD; Collen Harker MD; David Pisani, MD; Kathy Walker, RN. **Louisiana State University at Shreveport:** (1) PI: Claudio Schonholz, MD; Horacio D'Agostino, MD; Anil Nanda, MD; Roger Kelley, MD; Donna Singleton, RN. **State University of New York at Buffalo:** (1) PI: L. Nelson Hopkins, MD; Lee Guterman, MD; Elad Levy, MD; Jay Howington, MD; Mark Harrigan, MD; Ricardo Hanel, MD; Annemarie Crumlish. **University of North Carolina—Chapel Hill:** (1) PI: Sten Solander, MD; Ana Felix, MD; Souvik Sen, MD; David Huang, MD; Nydia Melendez, MD; Susan Wilson, MSN, FNP. **Washoe Medical Center:** (1) PI: Paul Katz, MD; Bradley Glenn, MD; Timothy Koci, MD; Anthony Bruno, MD; Mark Algood, MD; Marta Heffner, RN. **Baptist Memorial Clinical Research Center:** PI: John Barr, MD; Paul Broadbent, MD; Soren A. Singer, MD; Stephen D. Morris, MD; Sanat Dixit, MD; Grace Miller. **Barrow Neurological Institute:** PI: James Frey, MD; Cameron McDougall, MD; Felipe Albuquerque, MD; Mark Hekler, MD; David Fiorella, MD; Seth Larson, MD; Shafeeq Ladha, MD; Darin Okuda, MD; Mary Harrigan, RN, MN. **Baton Rouge General Hospital:** PI: Albert Alexander, MD; Joseph Acosta, MD; Jon Olson, MD; Kevin Callarame, MD; Rodney Hillis, MD; Kimberly Hendricks, RN, MN. **Emory University:** PI: Frank Tong, MD; Jacques Dion, MD; Michael Frankel, MD; Barney Stern, MD; Owen Samuels, MD; Marc Chimowitz, MD. **University of Texas, Houston:** PI: Morgan Campbell, MD; John Choi, MD; Frank Yatsu, MD; Marc Malkoff, MD; James Grotta, MD; Edwin Cacayorin, MD; Christina Hall, MD; Lise Labiche, MD; Elizabeth Noser, MD; Joon Song, MD; Ken Uchino, MD; Doralene Smith

### Acknowledgments

This study was funded by Concentric Medical Inc. Y.P.G. holds patent on the Concentric Retriever, holds stock in Concentric Medical, is a member of the Concentric Scientific Advisory board, and is director of Concentric Medical. G.N. was compensated as consultant for Concentric Medical, Inc. M.M.R. received a research grant from Concentric Medical, Inc. W.S.S. has received honoraria and has options to purchase stock in Concentric Medical, Inc. S.S. received research grants from Concentric Medical, Inc. G.S. was compensated for data safety monitoring board chairmanship from Concentric Medical, Inc.

### References

- Jansen O, von Kummer R, Forsting M, Hacke W, Sartor K. Thrombolytic therapy in acute occlusion of the intracranial internal carotid artery bifurcation. *AJNR Am J Neuroradiol.* 1995;16:1977–1986.
- Brandt T, von Kummer R, Muller-Kupfers M, Hacke W. Thrombolytic therapy of acute basilar artery occlusion. Variables affecting recanalization and outcome. *Stroke.* 1996;27:875–881.
- Bruckmann H, Ferbert A, del Zoppo GJ, Hacke W, Zeumer H. Acute vertebral-basilar thrombosis. Angiologic-clinical comparison and therapeutic implications. *Acta Radiol Suppl.* 1986;369:38–42.
- Hacke W, Schwab S, Horn M, Spranger M, De Georgia M, von Kummer R. "Malignant" middle cerebral artery territory infarction: clinical course and prognostic signs. *Arch Neurol.* 1996;53:309–315.
- Tissue plasminogen activator for acute ischemic stroke. The National Institute of Neurological Disorders and Stroke rt-PA Stroke Study Group. *N Engl J Med.* 1995;333:1581–1587.
- Furlan A, Higashida R, Wechsler L, Gent M, Rowley H, Kase C, Pessin M, Ahuja A, Callahan F, Clark WM, Silver F, Rivera F. Intra-arterial prourokinase for acute ischemic stroke. The PROACT II study: A randomized controlled trial. Prolyse in Acute Cerebral Thromboembolism. *JAMA.* 1999;282:2003–2011.
- Gobin YP, Starkman S, Duckwiler GR, Grobely T, Kidwell CS, Jahan R, Pile-Spellman J, Segal A, Vinuela F, Saver JL. Merci 1: a phase 1 study of mechanical embolus removal in cerebral ischemia. *Stroke.* 2004;35:2848–2854.
- Williams DO, Borer J, Braunwald E, Chesebro JH, Cohen LS, Dalen J, Dodge HT, Francis CK, Knatterud G, Ludbrook P, et al. Intravenous recombinant tissue-type plasminogen activator in patients with acute myocardial infarction: a report from the NHLBI thrombolysis in myocardial infarction trial. *Circulation.* 1986;73:338–346.
- IMS trial investigators. Combined intravenous and intra-arterial recanalization for acute ischemic stroke: the interventional management of stroke study. *Stroke.* 2004;35:904–911.
- Berger C, Fiorelli M, Steiner T, Schabitz WR, Bozzao L, Bluhmki E, Hacke W, von Kummer R. Hemorrhagic transformation of ischemic brain tissue: asymptomatic or symptomatic? *Stroke.* 2001;32:1330–1335.
- del Zoppo GJ, Poock K, Pessin MS, Wolpert SM, Furlan AJ, Ferbert A, Alberts MJ, Zivin JA, Wechsler L, Busse O, et al. Recombinant tissue plasminogen activator in acute thrombotic and embolic stroke. *Ann Neurol.* 1992;32:78–86.
- Berlis A, Lutsep H, Barnwell S, Norbash A, Wechsler L, Jungreis CA, Woolfenden A, Redekop G, Hartmann M, Schumacher M. Mechanical thrombolysis in acute ischemic stroke with endovascular photoacoustic recanalization. *Stroke.* 2004;35:1112–1116.
- Clark WM, Wissman S, Albers GW, Jhamandas JH, Madden KP, Hamilton S. Recombinant tissue-type plasminogen activator (alteplase) for ischemic stroke 3 to 5 hours after symptom onset. The ATLANTIS study: a randomized controlled trial. Alteplase thrombolysis for acute noninterventional therapy in ischemic stroke. *JAMA.* 1999;282:2019–2026.
- Hacke W, Kaste M, Fieschi C, von Kummer R, Davalos A, Meier D, Larrue V, Bluhmki E, Davis S, Donnan G, Schneider D, Diez-Tejedor E, Trouillas P. Randomised double-blind placebo-controlled trial of thrombolytic therapy with intravenous alteplase in acute ischaemic stroke (ECASS II). Second European-Australasian Acute Stroke Study Investigators. *Lancet.* 1998;352:1245–1251.
- Weimar C, Konig IR, Kraywinkel K, Ziegler A, Diener HC. Age and National Institutes of Health Stroke Scale score within 6 hours after onset are accurate predictors of outcome after cerebral ischemia: development and external validation of prognostic models. *Stroke.* 2004;35:158–162.
- Hacke W, Zeumer H, Ferbert A, Bruckmann H, del Zoppo GJ. Intra-arterial thrombolytic therapy improves outcome in patients with acute vertebrobasilar occlusive disease. *Stroke.* 1988;19:1216–1222.
- Suarez JI, Sunshine JL, Tarr R, Zaidat O, Selman WR, Kernich C, Landis DM. Predictors of clinical improvement, angiographic recanalization, and intracranial hemorrhage after intra-arterial thrombolysis for acute ischemic stroke. *Stroke.* 1999;30:2094–2100.
- Georgiadis D, Oehler J, Schwarz S, Rousson V, Hartmann M, Schwab S. Does acute occlusion of the carotid t invariably have a poor outcome? *Neurology.* 2004;63:22–26.
- Alexandrov AV, Molina CA, Grotta JC, Garami Z, Ford SR, Alvarez-Sabin J, Montaner J, Saqqur M, Demchuk AM, Moye LA, Hill MD, Wojner AW. Ultrasound-enhanced systemic thrombolysis for acute ischemic stroke. *N Engl J Med.* 2004;351:2170–2178.

## Editorial Comment

### Mechanical Embolus Removal A New Day Dawning

We must applaud the resourceful inventors, manufacturer, and investigators of the Merci Retriever device for completing the decade-long odyssey of directing the device through the design, development, study, and Food and Drug Administration (FDA) approval process. A number of devices have failed to climb that hill, falling back in pilot trials despite enthusiasm for their potential. However, previous editorials regarding approval of devices in general, and the potential Pandora's box of approval of the Merci Retriever in particular,<sup>1,2,3</sup> dictate that we evaluate the data that gained its approval as an embolectomy and revascularization device, as finally presented in this journal.

The device is intended to restore blood flow in the neurovasculature by removing thrombus in patients experiencing ischemic stroke.<sup>4</sup> The manuscript gives no confirmation that flow restoration in this study is due to thrombus removal (embolectomy), as opposed to clot disruption with proximal revascularization and distal embolization. Aggressive clot manipulation more quickly opens primary occlusions with fibrinolytic agent.<sup>5,6</sup> No substantive data on wire-based clot manipulation without lytic therapy exists. An abstract from the February 2005 issue of *Stroke* suggested 50% subject clot removal with use of the Merci device.<sup>7</sup> It was suggested that the 50% who might have a clot removed will be the same 50% that recanalize, and therefore that those who improve are among the 50% with clot removal. Nevertheless, even at that level of effectiveness, it is unclear that the device is doing what it is approved to do, which is to remove clots dependably. This embolectomy and/or revascularization issue seems a regulatory Scylla-and-Charybdis issue that might be of lesser import if clinical trial outcomes had been more impressive.

The primary Mechanical Embolus Removal in Cerebral Ischemia (MERCI) study outcome was the rate of recanalization of the terminal internal carotid artery (ICA-T), M1, M2, or basilar arteries, compared with 18% spontaneous recanalization of M1 or M2 in the Prolyse in Acute Cerebral Thromboembolism II (PROACT II) trial.<sup>8</sup> PROACT II had a central core laboratory for determining TIMI recanalization outcomes. The MERCI study reports Thrombolysis in Myocardial Infarction (TIMI) scores as determined by the operator. Unfortunately, interobserver variability in determination of recanalization efficacy hasn't been validated. An interim report from Interventional Management of Stroke II (IMS II) indicates a 41% discrepancy in central laboratory versus operator in ascribing TIMI flow, with the operator usually overscoring.

We still lack a conventional, validated revascularization analysis method, and this is an obstacle to comparing results obtained with one treatment paradigm to those with another.<sup>9</sup> The MERCI manuscript lacks a specific definition of TIMI recanalization as applied in this study, including recanaliza-

tion of the basilar artery. It seems clear that the authors evaluated recanalization of the primary occlusions in the ICA, M1, M2, and basilar arteries, and did not report distal perfusion or more distal MCA emboli.

The term "TIMI recanalization" or "TIMI perfusion/reperfusion" has been used with different meanings in different case series and studies. It has even been applied to magnetic resonance angiography (MRA) analysis. Recanalization does not equal reperfusion. Arteriographic demonstration of flow restoration, or revascularization, has two components: *recanalization* of the arterial occlusive lesion and subsequent proximal branches, and *reperfusion* into the distal arterial bed of the occluded vessel, including terminal branches with tissue staining, as applied in the original TIMI definition as an angiographic perfusion measure. Recanalization of the primary occlusion may be complete, but with variable distal patency and reperfusion because of preexisting emboli or emboli released by the revascularization procedure itself. The effect of distal emboli is not well understood in the setting of intra-arterial thrombolytic therapy, but is generally thought less deleterious than an unrecanalized proximal occlusion. Conversely, recanalization may be incomplete, with or without distal patency and perfusion, predisposing to reocclusion with clinical deterioration. The 2 components of revascularization have been analyzed in IMS I, and both (re)perfusion (taking distal flow and emboli limiting distal antegrade perfusion into account) and recanalization of the primary arterial occlusive lesion, have been associated with higher Rankin 0 to 2 outcome (P. Khatri, unpublished data, 2005). Other treatment paradigms might not achieve that same result.

The MERCI study fails to confirm that the recanalization definition and its application are comparable to those of PROACT II. In the absence of a guarantee of a comparable, reproducible definition of TIMI 2 to 3 reperfusion and its application, comparing the outcomes is difficult. Confirmatory post hoc analysis by the same core laboratory that reviewed arteriograms in PROACT II, using the same criteria, would be comforting. However, the PROACT core laboratory would need a convention for scoring recanalization and flow in revascularization of the carotid T occlusion and basilar artery occlusion, not evaluated in PROACT II.

The major complication rates reported are probably acceptable for patients with large deficits and poor predictable outcomes. Rates of symptomatic intracerebral hemorrhage (ICH) (the Achilles' heel of thrombolytic therapy), as well as asymptomatic ICH, seem acceptable. Vessel ruptures/perforations occurred, as they have elsewhere, including 3 of 64 (4.7%) patients in IMS I with no definite, direct, deleterious effect.<sup>10</sup> Distal emboli are a threat during a revascularization procedure, and 3 emboli to the anterior cerebral artery (ACA)

during middle cerebral artery (MCA) revascularization are reported in the MERCI study. However, that same phenomenon also occurs during MCA microcatheter thrombolysis: of 101 MCA occlusions in IMS I, and a local registry, 4 new ACA occlusions occurred during thrombolysis. Analysis of ACA emboli during 55 ICA-T occlusion thrombolysis treatments indicates 25% of patients had demonstrable occlusion beyond the A1 segment (A2-4) branches prior to therapy. Therapy led to 15% new, distal occlusions, not previously demonstrated, after therapy. In most T occlusions, ipsilateral ACA flow is maintained via the opposite carotid artery through the anterior communicating artery. Distal ACA emboli may lead to reduced collateral flow with MCA occlusion, which may be critical when MCA recanalization does not occur. New occlusions do occur during therapy, and we must find a way to identify and measure the effect of not only those in previously uninvolved distributions such as the ACA, but also more distal emboli in the MCA. Using both a vessel recanalization score, a perfusion score, a combination of both, or some other perfusion measure, may give us that insight. One treatment paradigm or device may differ from another in creating, or negating, secondary emboli.<sup>11</sup>

It is hard to digest the results so heavily weighted to historical comparison to observations from PROACT II, but with the primary and secondary efficacy outcome measures reversed. Certainly a drug that achieved 66% vessel recanalization seems as worthy of approval as a device with 50% recanalization. If the PROACT II study's primary efficacy outcome were based on the same recanalization measure, it succeeded more admirably than MERCI. Any revascularization study (performed in a reasonable time window) that examines Rankin 0 to 2 outcomes in recanalizers versus nonrecanalizers should prove effective! Recanalization has been shown to be associated with favorable outcome in numerous case series and studies. If the PROACT II study's secondary efficacy outcome were Rankin 0 to 2 outcomes in recanalizers versus nonrecanalizers, it may have been as or more successful than MERCI. Favorable secondary historical comparisons of the MERCI MCA group to the control group of PROACT II is tantalizing, but may be a siren's song to be avoided. Other variables may be confounding.

The mortality expected in the target group may be overstated according to other historical data. In the National Institute of Neurological Disorders and Stroke (NINDS) trial, mortality in the control group for patients of National Institutes of Health Stroke Scale (NIHSS) score >20, where the likelihood of a major occlusion must have been high, was 33%, compared with 43.5% overall mortality in the MERCI treated group. Mortality was 54.2% in the MERCI nonrecanalized group, increasing to 71% where adjuvant therapy was further applied unsuccessfully. This might be interpreted that the therapy attempt can do harm, and the more you do, the more harm can be done. The goal to reopen the vessel must first be tempered with recognition that 13% of the control group of NINDS with NIHSS score >20, and 25% of the control group of PROACT II, achieved independence.

Technical improvements are being made in the device. The device is appropriately being studied further in the Multi-

MERCI registry and MR-Rescue Trial. The device will be included for use in the forthcoming IMS III Trial, where 900 patients will be randomized to standard-dose IV alteplase versus reduced-dose alteplase followed by arterial intervention. Multi-Merci and IMS III may show that the device is more effective when applied at 3 to 4 hours after unsuccessful lytic therapy, rather than at 6 hours as in the MERCI trial. MR-Rescue should show that the device can be applied effectively up to 8 hours in subjects selected on the basis of diffusion/perfusion mismatch. Adjuvant therapies must be controlled and limited in these studies so that the issues of efficacy of the device aren't clouded by safety issues introduced by superimposed therapies with untested safety allowances, and limited further predictable benefit.

Certainly we have seen the rosy dawning of a new day in ischemic stroke therapy study. However, the MERCI device should be viewed as a stop along the path, and not the end of the journey itself.

**Thomas A. Tomsick, MD, FACR**  
*Radiology Department*  
*Section of Neuroradiology*  
*University of Cincinnati Hospital*  
*Cincinnati, Ohio*

## References

1. Furlan AJ, Fischer M. Devices, drugs, and the food and drug administration. Increasing implications for ischemic stroke. *Stroke*. 2005;36:398-399.
2. Becker KJ, Brott TG. Approval of the MERCI clot retriever. A critical review. *Stroke*. 2005;36:400-403.
3. Felten RP, Pena C, Provost MC, Schlosser MJ, Witten CM: The Food and Drug Administration medical device review process: clearance of a clot retriever for use in ischemic stroke. *Stroke*. 2005;36:404-406.
4. Neurological Device Panel Meeting, February 23, 2004. <http://www.fda.gov/ohrms/dockets/ac/04/transcripts/40221.htm>. Accessed June 6, 2005.
5. Noser EA, Shaltoni HM, Hall CE, Alexandrov AV, Garami Z, Cacayorin ED, Song JK, Grotta JC, Campbell MS 3rd: Aggressive mechanical clot disruption: a safe adjunct to thrombolytic therapy in acute stroke? *Stroke* 2005;36:292-296.
6. Qureshi AI, Siddiqui AM, Suri MF, Kim SH, Ali Z, Yahia AM, Lopes DK, Boulos AS, Ringer AJ, Saad M, Guterman LR, Hopkins LN: Aggressive mechanical clot disruption and low-dose intra-arterial third-generation thrombolytic agent for ischemic stroke: a prospective study. *Neurosurgery* 2002;51:1319-1329.
7. Marder V, Chute D, Starkman S, Abolian A; Kidwell C, Ovbiagele B, Vinuela F, Duckwiler G, Jahan R, Rajjee V, Selco S, Saver JL: Histology of thrombi retrieved from acute ischemic stroke patients by endovascular embolectomy. *Stroke*. 2005;36:516. [Abstract.]
8. Furlan A, Higashida R, Wechsler L, Gent M, Rowley H, Kase C, Pessin M, Ahuja A, Callahan F, Clark WM, Silver F, Rivera F. Intra-arterial prourokinase for acute ischemic stroke. The PROACT II study: a randomized controlled trial. *Prolyse in Acute Cerebral Thromboembolism*. *JAMA*. 1999;282:2003-2011.
9. Higashida RT, Furlan AJ, Roberts H, Tomsick T, Connors B, Barr J, Dillon W, Warach S, Broderick J, Tilley B, Sacks D; Technology Assessment Committee of the American Society of Interventional and Therapeutic Neuroradiology; Technology Assessment Committee of the Society of Interventional Radiology: Trial design and reporting standards for intra-arterial cerebral thrombolysis for acute ischemic stroke. *Stroke* 2003;34:e109-e137.
10. IMS Study Investigators. Combined intravenous and intra-arterial recanalization for acute ischemic stroke: the Interventional Management of Stroke (IMS) study. *Stroke*. 2004;35:904-912.
11. Yoneyama T, Nakano S, Kawano H, Iseda T, Ikeda T, Goya T, Wakisaka S: Combined direct percutaneous transluminal angioplasty and low-dose native tissue plasminogen activator therapy for acute embolic middle cerebral artery trunk occlusion. *AJNR Am J Neuroradiol*. 2002;23:277-281.