

Stroke

American Stroke
AssociationSM

JOURNAL OF THE AMERICAN HEART ASSOCIATION

A Division of American
Heart Association



Mechanical Thrombectomy of Intracranial Internal Carotid Occlusion. Pooled Results of the MERCI and Multi MERCI Part I Trials

Alexander C. Flint, Gary R. Duckwiler, Ronald F. Budzik, David S. Liebeskind, Wade S. Smith and for the MERCI and Multi MERCI Writing Committee

Stroke published online Mar 1, 2007;

DOI: 10.1161/01.STR.0000260187.33864.a7

Stroke is published by the American Heart Association, 7272 Greenville Avenue, Dallas, TX 75214
Copyright © 2007 American Heart Association. All rights reserved. Print ISSN: 0039-2499. Online
ISSN: 1524-4628

The online version of this article, along with updated information and services, is located on the World Wide Web at:

<http://stroke.ahajournals.org>

Subscriptions: Information about subscribing to *Stroke* is online at
<http://stroke.ahajournals.org/subscriptions/>

Permissions: Permissions & Rights Desk, Lippincott Williams & Wilkins, 351 West Camden Street, Baltimore, MD 21202-2436. Phone 410-5280-4050. Fax: 410-528-8550. Email:
journalpermissions@lww.com

Reprints: Information about reprints can be found online at
<http://www.lww.com/static/html/reprints.html>

Mechanical Thrombectomy of Intracranial Internal Carotid Occlusion

Pooled Results of the MERCI and Multi MERCI Part I Trials

Alexander C. Flint, MD, PhD; Gary R. Duckwiler, MD; Ronald F. Budzik, MD;
David S. Liebeskind, MD; Wade S. Smith, MD, PhD;
for the MERCI and Multi MERCI Writing Committee

Background and Purpose—Acute stroke from occlusion of the intracranial internal carotid artery (ICA) generally has a poor prognosis and appears to respond poorly to intravenous thrombolysis. Mechanical thrombectomy is a newly available modality for acute stroke therapy, but it is unknown whether this endovascular therapy may have a role in the specific setting of intracranial ICA occlusion. We therefore assessed the success rate of the Merci Retriever mechanical thrombectomy device in recanalization of intracranial ICA occlusions and sought to determine whether ICA recanalization with this therapy can result in better outcomes.

Methods—All patients with acute stroke from intracranial ICA occlusion were identified in the MERCI and Multi MERCI Part I trials. We determined the success rate of ICA recanalization with endovascular thrombectomy and then assessed clinical outcomes according to whether vessel recanalization was successful.

Results—Eighty patients with acute stroke from intracranial ICA occlusion were identified. Of these 80 patients, 53% had successful ICA recanalization with the Merci Retriever alone and 63% had ICA recanalization with use of the Merci Retriever plus adjunctive endovascular treatment. Baseline patient characteristics and procedural complications did not differ between the recanalized and nonrecanalized groups. Good clinical outcome, defined by a modified Rankin Scale of 0 to 2 at 90 days, occurred in 39% of patients with ICA recanalization (n=19 of 49) and in 3% of patients without ICA recanalization (n=1 of 30) ($P<0.001$; one patient was lost to follow up for 90-day modified Rankin Scale). Ninety-day mortality was 30% (n=15 of 50) in the recanalized group and 73% (n=22 of 30) in the nonrecanalized group ($P<0.001$). Symptomatic hemorrhage was not significantly different between the recanalized (6% [n=3 of 50]) and nonrecanalized (16.7% [n=5 of 30]) groups ($P=0.14$). Hemorrhage rates were also not found to be influenced by use of intravenous thrombolysis before mechanical thrombectomy. Multivariable logistic regression identified ICA recanalization (OR=28.4, 95% CI=2.6 to >99.9) and lack of history of hypertension (OR=0.15, 95% CI=0.04 to 0.57) as significant predictors of a good 90-day outcome. Failure to recanalize the ICA (OR=0.16, 95% CI=0.05 to 0.51) and age (per decade, OR=1.07, 95% CI=1.03 to 1.13) were significant predictors of mortality at 90 days.

Conclusions—Mechanical thrombectomy of acute intracranial ICA occlusion using the Merci Retriever device, alone or in combination with adjunctive endovascular therapy, has a high rate of successful vessel recanalization. Subjects with successful ICA recanalization by this method have improved poststroke clinical outcome and survival compared with subjects in which the ICA is not successfully recanalized. (*Stroke*. 2007;38:000-000.)

Key Words: acute stroke ■ endovascular treatment ■ internal carotid artery ■ thrombectomy

Occlusion of the intracranial internal carotid artery (ICA) is a potentially catastrophic event. If the distal intracranial ICA is occluded and there is a significant initial deficit, the outcome is usually very poor. Such patients have a high mortality rate and are often refractory to thrombolysis.¹⁻³ Estimates of the natural history of ICA occlusion suggest that only 2% to 12% will go on to have a good recovery, 40% to

69% are left with a severe deficit, and 16% to 55% will die as a result of their infarct, depending on the duration of follow up.⁴

Because of the poor prognosis and poor response of ICA occlusion to intravenous (IV) thrombolysis, various procedural approaches to acute recanalization have been explored, including emergency carotid endarterectomy for acute extracranial occlusions,⁴ balloon angioplasty,⁵ intraarterial (IA)

Received September 19, 2006; final revision received November 8, 2006; accepted November 15, 2006.

From the Department of Neurology (A.C.F., W.S.S.), University of California, San Francisco, San Francisco, Calif.; the Departments of Radiology (G.R.D.) and Neurology (D.S.L.), University of California, Los Angeles, Los Angeles, Calif.; and the Department of Radiology (R.F.B.), Riverside Methodist Hospital, Columbus, Ohio.

Correspondence to Alexander C. Flint, MD, PhD, University of California, San Francisco, Neurovascular Service and Neurocritical Care, 505 Parnassus Ave, San Francisco CA 94143-0114. E-mail alex.flint@ucsfmedctr.org

© 2007 American Heart Association, Inc.

Stroke is available at <http://www.strokeaha.org>

DOI: 10.1161/01.STR.0000260187.33864.a7

thrombolysis and combined IV/IA thrombolysis,^{2,6-10} IA thrombolytic plus balloon angioplasty,¹¹ an endovascular microsnares device,¹² and mechanical clot disruption plus thrombolytics.^{13,14} The recent clearance in the United States of an endovascular thrombectomy device, the Merci Retrieval System (Concentric Medical, Inc., Mountain View, Calif.), raises the possibility that mechanical thrombectomy might have a role in the treatment of acute ICA occlusions.

We therefore pooled data from the MERCI trial and Part I of the Multi MERCI trial to explore the clinical outcomes in patients with acute stroke from intracranial ICA occlusion. We describe the safety and efficacy of mechanical thrombectomy in 80 patients with intracranial ICA occlusion and report 3-month clinical outcomes in these patients according to recanalization status.

Methods

Data for the present analysis were derived from two clinical trials of the Merci Retrieval System: the "MERCI" trial and the "Multi MERCI" trial. Both trials were conducted in two parts each as described elsewhere.^{15,16}

Patients and Techniques

MERCI was a single-arm multicenter trial. The study tested whether a mechanical thrombectomy device could safely restore vascular patency at a rate exceeding a prespecified rate of spontaneous recanalization in patients presenting within 8 hours of onset of an acute ischemic stroke.¹⁵ Multi MERCI is a single-arm, multicenter trial that included both IV tissue plasminogen activator (t-PA)-ineligible and IV t-PA-treated patients. Patient eligibility in the IV t-PA ineligible arm of Multi MERCI was the same as for MERCI.^{15,16} Eligibility in the IV t-PA-treated arm was the same as in the IV t-PA-ineligible arm except that patients who had received t-PA within 3 hours of onset under U.S. Food and Drug Administration-labeled indications could be enrolled if t-PA failed to open the intracranial large vessel as determined by angiography. Details of patient enrollment in MERCI and Multi MERCI, including inclusion and exclusion criteria, have been previously described.^{15,16}

Thrombectomy Procedure

Details of the devices and procedures used in MERCI^{15,17} and Multi MERCI¹⁶ have been previously published. Up to six device passes were allowed. Successful recanalization was defined as achieving at Thrombolysis In Myocardial Infarction¹⁸ II or III flow in all treatable vessels, as in PROACT-II¹⁹ and IMS.⁹ Successful recanalization for intracranial ICA lesions required the ICA, M1, and M2 branches to have flow restored to at least Thrombolysis In Myocardial Infarction II. Intraarterial thrombolytics were allowed in cases of treatment failure with the device after six passes or to treat distal embolus not accessible to the device after successful proximal thrombectomy. Angioplasty and stenting of any lesion were not allowed.

Clinical Variables and Measurement of Outcome

Measurement of baseline clinical variables and clinical outcomes was similar in MERCI and Multi MERCI, as previously described.^{15,16} Computed tomography brain imaging was performed at 24 hours or for any decline in neurologic status. Symptomatic intracranial hemorrhage was defined as a 4 or more point worsening of the National Institutes of Health Stroke Scale (NIHSS) score within 24 hours with any blood products identified on head computed tomography scan. All computed tomography scans were reviewed in a core laboratory. Hemorrhages were adjudicated by the Data Safety Monitoring Board (DSMB).

Primary outcomes were recanalization and device-related complications. Device-related complications were defined as vascular perforation, arterial dissection, or embolization of an uninvolved territory. Clinically significant procedure complications were de-

defined as a procedure complication with worsening of NIHSS by ≥ 4 , any subarachnoid hemorrhage, or any groin complication requiring surgery or blood transfusion. Secondary outcomes included the modified Rankin Scale (mRS) and NIHSS at 30 and 90 days. Good neurologic outcome was prespecified as mRS ≤ 2 .

Statistical Analysis

Categorical data in contingency tables were analyzed by the Fisher exact test. Continuous data were assessed for normality by the Kolmogorov-Smirnov test; normally distributed continuous data were analyzed by *t* test, and continuous data not passing this normality test were compared using the Mann-Whitney test. The percentage of patients with successful recanalization with mechanical thrombectomy was compared with the benchmark rate of 18% spontaneous middle cerebral artery (MCA) recanalization from the control arm of PROACT II²⁰ using the binomial test. Univariable analyses were separately performed modeling good outcome (mRS=0 to 2) at 90 days or mortality at 90 days. All variables with $P < 0.2$ in univariable analysis were entered into separate multivariable logistic regression models of good outcome (mRS=0 to 2) at 90 days and mortality at 90 days. Models were built using forward/backward stepwise logistic regression with variables entered into the model at the 0.05 significance level and removed at the 0.10 significance level. Statistical analyses were performed using STATA and SAS.

Results

In the combined series of MERCI and Multi MERCI Part I, 80 patients with angiographically proven intracranial ICA occlusion were enrolled. Of these, 47 were enrolled in MERCI and 33 were enrolled in Multi MERCI Part I. Mean patient age was 67 ± 16 years (median=72, interquartile range=57.5 to 80 years). Mean presentation NIHSS score was 20 ± 5 (median=20, interquartile range=17 to 23). Of the 33 Multi MERCI Part I patients, 11 (33%) received intravenous t-PA before angiography; the remaining 22 Multi MERCI intracranial ICA patients were IV t-PA-ineligible. Overall, 14% of the patients in our analysis received IV t-PA ($n=11$ of 80). Mean time elapsed from stroke onset to arterial access was 4.1 ± 1.6 hours (median=3.9, interquartile range=3.0 to 5.4 hours). The generation of Merci thrombectomy device used was as follows: X series alone in 58 patients, L5 alone in 16 patients, and L5+X series in six patients.

Recanalization of the intracranial ICA was achieved in 53% with the Merci Retriever alone ($n=42$ of 80). The 53% rate of ICA recanalization after use of the Merci Retriever alone is significantly higher than the 18% benchmark rate^{15,20} ($P < 0.001$, two-tailed binomial test). Sixty-three percent ($n=50$ of 80) had vessel recanalization after both Merci Retriever use and adjunctive treatment with IA thrombolytics. The remaining 37% ($n=30$ of 80) did not have recanalization of the occluded ICA by the end of the procedure. Of the 38 ICA occlusions that did not open with the Merci Retriever alone, 16 received adjunctive IA thrombolysis, and of these, eight went on to recanalize with adjunctive treatment. Adjunctive IA thrombolytics were used in a total of 23 patients: 16 of 38 patients with vessel occlusions that failed to recanalize with the Merci Retriever and seven of 42 patients in which the Merci Retriever produced at least Thrombolysis In Myocardial Infarction grade II flow at the occlusion site and IA thrombolysis was used to treat residual clot burden at the occlusion site or more distally. The adjunctive thrombolytic

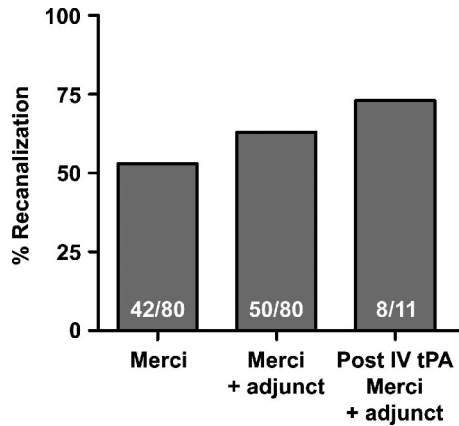


Figure 1. Recanalization rates. Bar graphs indicate the rate of internal carotid artery recanalization after attempted thrombectomy alone, attempted thrombectomy followed by adjunctive intraarterial thrombolysis, and both maneuvers in the subset of patients who had received intravenous tissue plasminogen activator before thrombectomy.

used was t-PA in 21 of 23 (mean dose=13.2±8.9 mg IA), urokinase in one of 23 (250 000 IU IA), and tenecteplase in one of 23 (5 mg IA). Among the patients with ICA occlusion who were enrolled in Multi MERCI after failed IV thrombolysis, eight of 11 (73%) had successful recanalization by the end of the procedure (Figure 1).

Baseline patient characteristics for the overall patient population and for the successful recanalization and failed

recanalization groups are shown in Table 1. No significant differences in baseline characteristics were detected between the recanalized and nonrecanalized groups.

Good clinical outcome, as determined by a mRS of 0 to 2 at 90 days, occurred more often in patients who had successful ICA recanalization (Table 2; Figure 2). Among patients with postprocedure ICA recanalization, 39% (n=19 of 49) had a mRS of 0 to 2 at 90 days, whereas 3% (n=1 of 30) of patients with failed recanalization had an mRS of 0 to 2 at 90 days ($P<0.001$). Among survivors at 90 days, an mRS of 0 to 2 was seen in 55.9% (n=19 of 34) of the recanalized group and 12.5% (n=1 of 8) of the nonrecanalized group ($P=0.047$). Overall, 25% of the ICA occlusion patients in MERCI and Multi MERCI Part I (n=20 of 79) had a good neurologic outcome at 90 days poststroke (mRS=0 to 2). One patient in the recanalized group was lost to follow up for assessment of the mRS.

There was also a difference in 90-day mortality observed between the recanalized and nonrecanalized groups. At 90 days poststroke, 30% (n=15 of 50) of the recanalized patients were dead, whereas 73% (n=22 of 30) of the nonrecanalized patients were dead ($P<0.001$). The overall mortality was 46% (n=37 of 80) at 90 days poststroke.

In contrast, there was no significant difference in the rate of symptomatic intracranial hemorrhage between the recanalized and nonrecanalized groups. Symptomatic hemorrhage was observed in 6% (n=3 of 50) of the patients with ICA recanalization and in 16.7% (n=5 of 30) of the patients

TABLE 1. Patient Characteristics

	Recanalized	Not Recanalized	Total	P
Mean Age, years±SD	66±16	70±14	67±16	0.32
Female sex	44% (22/50)	53% (16/30)	48% (38/80)	0.49
Hypertension	55% (27/49)	72% (21/29)	62% (48/78)	0.15
Diabetes mellitus	12% (6/50)	10% (3/29)	11% (9/79)	>0.99
Dyslipidemia	33% (15/45)	27% (7/26)	31% (22/71)	0.61
Coronary artery disease	43% (21/49)	52% (15/29)	46% (36/78)	0.49
Congestive heart failure	16% (8/50)	14% (4/28)	15% (12/78)	>0.99
Smoking	29% (14/48)	29% (8/28)	29% (22/76)	>0.99
Atrial fibrillation	34% (17/50)	38% (11/29)	35% (28/79)	0.81
Body mass index	27.1±5.1 (n=42)	29.1±7.2 (n=25)	27.8±6.0 (n=67)	0.87
National Institutes of Health Stroke Scale score at onset	20±5	20±6	20±5	0.65
Failed intravenous tissue plasminogen activator before MERCI	16% (8/50)	10% (3/30)	14% (11/80)	0.52
Symptom onset to groin puncture (h)	4.1±1.5	4.3±1.7	4.1±1.6	0.58
Left-sided internal carotid artery occlusion	62.0% (31/50)	60.0% (18/30)	61.3% (49/80)	>0.99
Mean procedure duration (h)	1.85±0.79	2.15±0.87	1.97±0.83	0.11
Procedural complications (includes nondevice complications)				
Total	6% (3/50)	10% (3/30)	7.5% (6/80)	0.67
Clinically significant procedure-related adverse events	4% (2/50)	10% (3/30)	6.3% (5/80)	0.36

Data are presented either as percent of group (no. in group/total in group) or as no.±SD. P values are for Fisher exact test comparing recanalized and nonrecanalized groups with categorical data, t test comparison between the recanalized and nonrecanalized groups in the case of National Institutes of Health Stroke Scale score at onset and symptom onset to groin puncture, and Mann-Whitney test comparisons for age, body mass index, and procedure duration.

TABLE 2. Clinical Outcomes

	Recanalized	Not Recanalized	Total	<i>P</i>
Modified Rankin Score (mRS) at 90 days				0.004*
mRS=0	16.3% (8/49)	0% (0/30)	10.1% (8/79)	
mRS=1	10.2% (5/49)	0% (0/30)	6.3% (5/79)	
mRS=2	12.2% (6/49)	3.3% (1/30)	8.9% (7/79)	
mRS=3	12.2% (6/49)	10% (3/30)	11.4% (9/79)	
mRS=4	14.3% (7/49)	10% (3/30)	12.7% (10/79)	
mRS=5	4.1% (2/49)	3.3% (1/30)	3.8% (3/79)	
Mortality at 90 days (mRS=6)	30% (15/50)	73% (22/30)	46% (37/79)	<0.001
Good outcome (mRS=0 to 2) at 90 days, overall	39% (19/49)	3% (1/30)	25% (20/79)	<0.001
Good outcome (mRS=0 to 2) at 90 days among survivors	55.9% (19/34)	12.5% (1/8)	47.6% (20/42)	0.047
Symptomatic hemorrhage	6% (3/50)	16.7% (5/30)	10% (8/80)	0.14

For mRS, data were unavailable for one patient; thus, data are derived from 79 patients. For mRS (0 to 5), percentages shown reflect percent of survivors in either category. *P* values shown are for Fisher exact test comparing recanalized and nonrecanalized groups.

**P* value in the upper right is for the Fisher exact test comparing the distribution of the full range of mRS (0 to 6) in recanalized and nonrecanalized groups.

without recanalization ($P=0.14$). The symptomatic hemorrhage rate was 10% ($n=8$ of 80) for the overall population, 9.1% ($n=1$ of 11) for the subgroup of patients who received IV thrombolysis before endovascular treatment, and 10.1% ($n=7$ of 69) among patients who did not receive IV thrombolysis ($P>0.99$). Symptomatic hemorrhage occurred in one of eight patients who failed IV t-PA but went on to have successful ICA recanalization after thrombectomy, whereas none patients who failed IV t-PA and failed to recanalize with thrombectomy had symptomatic hemorrhage ($P>0.99$). In the six patients given IV t-PA but no adjunctive IA thrombolysis, there were no symptomatic hemorrhages. Similarly, none of the four patients who received IA t-PA after IV t-PA had a symptomatic hemorrhage. Of the 23 patients who received adjunctive IA thrombolysis, one patient had a symptomatic hemorrhage; this patient received IA tenecteplase after receiving IV t-PA before attempted thrombectomy. Of the 51 patients who received no thrombolytics, either IV or IA, seven (13.7%) had symptomatic hemorrhage. Of the eight patients with symptomatic hemorrhage in the total patient population, seven of eight (87.5%) died by 90 days poststroke compared with 30 of 72 (41.7%) patients

without symptomatic hemorrhage who died by 90 days ($P=0.02$).

Of the eight symptomatic hemorrhages in the total patient population ($n=80$), three were associated with a vessel perforation, and all three were in the nonrecanalized group. Therefore, 3.8% of all treated patients ($n=3$ of 80) had symptomatic hemorrhage from a procedural complication; all three of these patients died. Two other clinically significant procedural complications occurred. One patient had an intracranial vessel dissection associated with the balloon guide catheter without symptomatic hemorrhage. This patient died between the 30- and 90-day visits. Another patient had a complication of femoral artery access that required surgical repair. One procedural complication occurred that was adjudicated to be not clinically significant in which an intracranial dissection occurred without symptomatic hemorrhage. This patient was alive with a good neurologic outcome (mRS=1) at 90 days. Of the five clinically significant adverse events in the total patient population, two occurred among the 50 recanalized patients and three occurred among the 30 patients who did not have ICA recanalization ($P=0.36$). When the five patients with significant adverse events are excluded, the

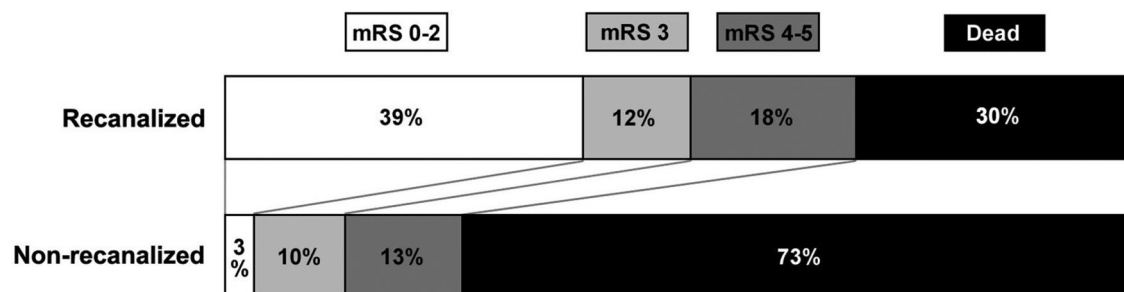


Figure 2. Clinical outcomes according to recanalization status. Modified Rankin Scale (mRS) is displayed as good neurologic outcome (mRS=0 to 2), intermediate neurologic outcome (mRS=3), poor neurologic outcome (mRS=4 to 5), or death (mRS=6). A significantly higher percentage of patients in the recanalized group had good neurologic outcome at 90 days, whereas a significantly lower percentage of patients in the nonrecanalized group were dead at 90 days.

TABLE 3. Multivariable Logistic Regression: 90-Day Modified Rankin Scale (mRS) and Mortality

Variable	mRS 0 to 2		Mortality	
	OR (95% CI)	P Value	OR (95% CI)	P Value
Recanalized	28.4 (2.6 to >99.9)	0.006	0.16 (0.05 to 0.51)	0.002
Hypertension	0.15 (0.04 to 0.57)	0.005
National Institutes of Health Stroke Scale score	0.86 (0.74 to 1.00)	0.05
Age group (decade)	1.07 (1.03 to 1.13)	0.002
Hemorrhage	8.8 (0.83 to 92.5)	0.07

The two logistic regression models, predicting good outcome (mRS=0 to 2) and mortality, respectively, were built using forward/backward stepwise logistic regression using variables with *P*<0.2 significance in univariable logistic regression entered at the 0.05 significance level and removed at the 0.1 significance level. In the model of good outcome, hemorrhage was dropped as a result of estimability (zero of eight patients with hemorrhage had a good outcome).

relationships between recanalization and good outcome and recanalization and mortality are not affected.

To determine which baseline patient variables and trial-related variables impacted outcome and survival, we performed regression analysis on the outcomes of 90-day mRS 0 to 2 and 90-day mortality. In multivariable logistic regression analysis, lack of history of hypertension and ICA recanalization significantly predicted good outcome (mRS=0 to 2) at 90 days, and NIHSS had a borderline significant effect on good outcome (Table 3). Failure of ICA recanalization and age group by decade significantly predicted 90-day mortality (Table 3). Thus, successful ICA recanalization remained a positive predictor of 90-day good outcome (mRS=0 to 2) and a negative predictor of 90-day mortality when other variables were held constant in multivariable regression. When the same models were built without the five patients with significant adverse events, lack of history of hypertension, ICA recanalization, and NIHSS still predicted good outcome (mRS=0 to 2) at 90 days, and recanalization failure and age group by decade still predicted mortality at 90 days (data not shown).

Discussion

Our data show an association between recanalization of intracranial ICA occlusion and good clinical outcomes. We find a much lower rate of mortality in patients with ICA occlusions who were successfully recanalized. There was no observed difference in symptomatic hemorrhage rates between recanalized and nonrecanalized ICA occlusion patients.

The rate of successful ICA recanalization with the Merci Retriever was high (Figure 1), but there are no angiographic control data to establish the rate of spontaneous ICA recanalization in acute stroke. The 18% angiographically confirmed spontaneous recanalization of proximal MCA occlusions in the control arm of PROACT-II was used as a benchmark rate¹⁵ and may overestimate spontaneous ICA recanalization.³ In one recent series of patients with intracranial ICA occlusion studied with transcranial Doppler, 17% of patients not treated with thrombolytics showed complete or partial recanalization in the first 24 hours.²¹

The rate of ICA recanalization with the Merci device compares favorably with case series of thrombolysis for ICA occlusion. ICA recanalization in one study of intravenous t-PA occurred in 26%.³ The rate of recanalization of tandem MCA occlusions was 59% (complete in 35%, partial in 24%).³ Larger series of isolated proximal MCA occlusions support this discrepancy between middle cerebral artery and ICA recanalization rates.²² In another series of patients comparing IV t-PA treatment in patients with ICA or MCA occlusions, there was also a much lower rate of ICA recanalization (31%) compared with MCA recanalization (88%) at 3 days after t-PA.¹ In two studies that used angiography after IV t-PA administration, only approximately 8% of patients with intracranial ICA occlusion showed early recanalization with t-PA.^{23,24} One study of patients with intracranial ICA occlusion followed by transcranial Doppler found that 12 of 18 patients treated with IV t-PA showed recanalization,²¹ a much higher rate of recanalization than reported elsewhere. Among patients who received IA urokinase for acute ICA occlusions, recanalization was seen in 42%.⁸ In a series reporting treatment of ICA occlusions with intravenous t-PA, IA t-PA, or IA urokinase, the rate of recanalization was low (12.5%).² In another small series using IA thrombolysis, 63% of ICA occlusions had partial recanalization and 46% had complete recanalization.⁷ Although few patients with intracranial ICA occlusion were reported in the IMS “bridging” trial (IV+IA t-PA), successful ICA recanalization was seen in nine of 20 patients.⁹ In a series of 18 patients treated with either IA or combined IV/IA thrombolytics, complete recanalization was reported in 62% of patients receiving IA therapy alone and in 80% of patients receiving combined IV/IA thrombolysis.⁶ In the same report, a summary of previous small ICA series reported a combined IV/IA rate of recanalization of 69% (nine of 13 patients) and a 10% to 38% rate of recanalization with IA treatment alone.⁶ The combination of mechanical clot disruption with IA thrombolysis was found to produce recanalization in nine of 11 patients in one series.¹⁴

The literature on the natural history of ICA occlusion is limited, but it is clear that untreated ICA stroke carries a poor prognosis, except when the presenting stroke symptoms are

mild and the degree of collateral flow is robust. Among 40 patients with ICA occlusion, the majority (22 of 40) had a severe stroke, and nearly all of those with a severe stroke were significantly disabled (nine of 22 [41%]) or dead (12 of 22 [55%]) at 2-year follow up.²⁵ In a series of 179 patients with clinically diagnosed carotid occlusion, mortality appeared to vary based on alteration of consciousness at presentation (41% of patients with abnormal level of consciousness died compared with 2% of those with normal-level consciousness).²⁶

Clinical outcomes in patients with ICA occlusions treated with thrombolytics are also poor in most series. In one small series, treatment of angiographically confirmed intracranial ICA occlusion with either IV or IA thrombolysis resulted in an outcome of severe neurologic disability or death in 80%.² A series of patients with transcranial Doppler-documented intracranial ICA occlusion treated with IV t-PA reported an outcome of severe disability or death in 40%.³ In a small series of patients treated with IA urokinase, patients with distal ICA occlusions had worse outcomes compared with other sites of occlusion.²⁷ Among 18 patients treated with IA and IV thrombolytics, the 90-day mortality rate was 50%, and symptomatic intracranial hemorrhage was seen in 22%.⁶ In another study, 17% had a good outcome at 90 days (mRS= \leq 2) and 42% died by 90 days.⁷ However, better outcomes were reported in a small series of ICA patients treated with combined IA urokinase and mechanical clot disruption with good outcomes in four of 11 patients and mortality in only one of 11.¹⁴

The MERCI and Multi MERCI trials have not included a nontreatment arm. Thus, these data cannot directly demonstrate that mechanical thrombectomy of acute intracranial ICA occlusions is superior to nontreatment. However, our data do show that the Merci device, together with adjunctive therapy, allows for a high rate of ICA recanalization and that ICA recanalization is associated with better clinical outcome and survival. The baseline patient characteristics did not differ between those who were successfully recanalized and those who were not, and therefore it is unlikely that confounding biased our results. Removal of the five patients with clinically significant adverse events from our analyses did not alter the results, so procedure-related complications in the nonrecanalized group cannot explain the apparent effect of recanalization on good outcome or mortality. In multivariable logistic regression, ICA recanalization was a positive predictor of 90-day good outcome and negative predictor of 90-day mortality. Interestingly, the time from stroke onset to procedure was not an independent predictor of either outcome measure (but all patients were treated in the <8-hour time window). Because the rate of ICA recanalization with the Merci Retriever far exceeds the expected rate of spontaneous early recanalization, mechanical thrombectomy for acute ICA occlusion <8 hours from stroke onset in an appropriately selected patient population is likely to be clinically beneficial.

Further study is needed to determine the effect of ICA recanalization on outcome in subsets of patients with particular ICA occlusion patterns (ICA versus ICA/MCA, ICA/MCA/anterior cerebral artery, or "T occlusion") and according to the degree of collateral blood flow before

recanalization. Given that adjunctive use of thrombolytics with attempted thrombectomy appears to be safe in this population, selective adjunct use of thrombolytics should be considered, for example, to recanalize the carotid terminus to improve collateral flow should thrombectomy fail to recanalize the ICA. In light of the high recanalization rate of mechanical thrombectomy for ICA occlusion, a comparison of mechanical thrombectomy to intravenous thrombolysis in the <3-hour time window is warranted.

Disclosures

A.C.F. has nothing to disclose; G.R.D. has stock ownership in Concentric Medical; R.F.B. is a consultant for Concentric Medical; D.S.L. is a consultant for Concentric Medical; W.S.S. was the Principal Investigator, MERCI and Multi MERCI trials and has stock ownership in Concentric Medical.

References

1. Linfante I, Llinas RH, Selim M, Chaves C, Kumar S, Parker RA, Caplan LR, Schlaug G. Clinical and vascular outcome in internal carotid artery versus middle cerebral artery occlusions after intravenous tissue plasminogen activator. *Stroke*. 2002;33:2066–2071.
2. Jansen O, von Kummer R, Forsting M, Hacke W, Sartor K. Thrombolytic therapy in acute occlusion of the intracranial internal carotid artery bifurcation. *AJNR Am J Neuroradiol*. 1995;16:1977–1986.
3. Christou I, Felberg RA, Demchuk AM, Burgin WS, Malkoff M, Grotta JC, Alexandrov AV. Intravenous tissue plasminogen activator and flow improvement in acute ischemic stroke patients with internal carotid artery occlusion. *J Neuroimaging*. 2002;12:119–123.
4. Meyer FB, Sundt TM Jr, Piepgras DG, Sandok BA, Forbes G. Emergency carotid endarterectomy for patients with acute carotid occlusion and profound neurological deficits. *Ann Surg*. 1986;203:82–89.
5. Song JK, Cacayorin ED, Campbell MS, Fisher S, Malkoff MD, Alexandrov AV, Grotta JC. Intracranial balloon angioplasty of acute terminal internal carotid artery occlusions. *AJNR Am J Neuroradiol*. 2002;23:1308–1312.
6. Zaidat OO, Suarez JJ, Santillan C, Sunshine JL, Tarr RW, Paras VH, Selman WR, Landis DM. Response to intra-arterial and combined intravenous and intra-arterial thrombolytic therapy in patients with distal internal carotid artery occlusion. *Stroke*. 2002;33:1821–1826.
7. Arnold M, Nedeltchev K, Mattle HP, Loher TJ, Stepper F, Schroth G, Brekenfeld C, Sturzenegger M, Remonda L. Intra-arterial thrombolysis in 24 consecutive patients with internal carotid artery t occlusions. *J Neurol Neurosurg Psychiatry*. 2003;74:739–742.
8. Jahan R, Duckwiler GR, Kidwell CS, Sayre JW, Gobin YP, Villablanca JP, Saver J, Starkman S, Martin N, Vinuela F. Intraarterial thrombolysis for treatment of acute stroke: Experience in 26 patients with long-term follow-up. *AJNR Am J Neuroradiol*. 1999;20:1291–1299.
9. IMS Trial Investigators. Combined intravenous and intra-arterial recanalization for acute ischemic stroke: the Interventional Management of Stroke Study. *Stroke*. 2004;35:904–911.
10. Sugg RM, Noser EA, Shaltoni HM, Gonzales NR, Campbell MS, Weir R, Cacayorin ED, Grotta JC. Intra-arterial reteplase compared to urokinase for thrombolytic recanalization in acute ischemic stroke. *AJNR Am J Neuroradiol*. 2006;27:769–773.
11. Watanabe M, Mori T, Imai K, Izumoto H, Kamiya T. Intra-arterial fibrinolysis combined with balloon angioplasty in patients with serious symptoms due to acute embolic total occlusion of the carotid artery [Abstract]. *Stroke*. 2004;35:298.
12. Imai K, Mori T, Izumoto H, Watanabe M. Successful thrombectomy in acute terminal internal carotid occlusion using a basket type microsnare in conjunction with temporary proximal occlusion: a case report. *AJNR Am J Neuroradiol*. 2005;26:1395–1398.
13. Noser EA, Shaltoni HM, Hall CE, Alexandrov AV, Garami Z, Cacayorin ED, Song JK, Grotta JC, Campbell MS 3rd. Aggressive mechanical clot disruption: a safe adjunct to thrombolytic therapy in acute stroke? *Stroke*. 2005;36:292–296.
14. Sorimachi T, Fujii Y, Tsuchiya N, Nashimoto T, Harada A, Ito Y, Tanaka R. Recanalization by mechanical embolus disruption during intra-arterial thrombolysis in the carotid territory. *AJNR Am J Neuroradiol*. 2004;25:1391–1402.

15. Smith WS, Sung G, Starkman S, Saver JL, Kidwell CS, Gobin YP, Lutsep HL, Nesbit GM, Grobelny T, Rymer MM, Silverman IE, Higashida RT, Budzik RF, Marks MP. Safety and efficacy of mechanical embolectomy in acute ischemic stroke: results of the MERCI Trial. *Stroke*. 2005;36:1432–1438.
16. Smith WS. Safety of mechanical thrombectomy and intravenous tissue plasminogen activator in acute ischemic stroke. Results of the Multi Mechanical Embolus Removal in Cerebral Ischemia (MERCI) trial, part I. *AJNR Am J Neuroradiol*. 2006;27:1177–1182.
17. Gobin YP, Starkman S, Duckwiler GR, Grobelny T, Kidwell CS, Jahan R, Pile-Spellman J, Segal A, Vinuela F, Saver JL. MERCI 1: a phase 1 study of Mechanical Embolus Removal in Cerebral Ischemia. *Stroke*. 2004;35:2848–2854.
18. Williams DO, Borer J, Braunwald E, Chesebro JH, Cohen LS, Dalen J, Dodge HT, Francis CK, Knatterud G, Ludbrook P, et al. Intravenous recombinant tissue-type plasminogen activator in patients with acute myocardial infarction: a report from the NHLBI Thrombolysis in Myocardial Infarction Trial. *Circulation*. 1986;73:338–346.
19. Furlan A, Higashida R, Wechsler L, Gent M, Rowley H, Kase C, Pessin M, Ahuja A, Callahan F, Clark WM, Silver F, Rivera F. Intra-arterial prourokinase for acute ischemic stroke. The PROACT II study: a randomized controlled trial. PROlyse in Acute Cerebral Thromboembolism. *JAMA*. 1999;282:2003–2011.
20. del Zoppo GJ, Higashida RT, Furlan AJ, Pessin MS, Rowley HA, Gent M. PROACT: a phase II randomized trial of recombinant pro-urokinase by direct arterial delivery in acute middle cerebral artery stroke. PROACT Investigators. PROlyse in Acute Cerebral Thromboembolism. *Stroke*. 1998;29:4–11.
21. Georgiadis D, Oehler J, Schwarz S, Rousson V, Hartmann M, Schwab S. Does acute occlusion of the carotid t invariably have a poor outcome? *Neurology*. 2004;63:22–26.
22. Labiche LA, Malkoff M, Alexandrov AV. Residual flow signals predict complete recanalization in stroke patients treated with tPA. *J Neuroimaging*. 2003;13:28–33.
23. del Zoppo GJ, Poeck K, Pessin MS, Wolpert SM, Furlan AJ, Ferbert A, Alberts MJ, Zivin JA, Wechsler L, Busse O, et al. Recombinant tissue plasminogen activator in acute thrombotic and embolic stroke. *Ann Neurol*. 1992;32:78–86.
24. Wolpert SM, Bruckmann H, Greenlee R, Wechsler L, Pessin MS, del Zoppo GJ. Neuroradiologic evaluation of patients with acute stroke treated with recombinant tissue plasminogen activator. The rt-PA Acute Stroke Study Group. *AJNR Am J Neuroradiol*. 1993;14:3–13.
25. McDowell FH, Potes J, Groch S. The natural history of internal carotid and vertebral–basilar artery occlusion. *Neurology*. 1961;11:153–157.
26. Jones HR Jr, Millikan CH, Sandok BA. Temporal profile (clinical course) of acute vertebrobasilar system cerebral infarction. *Stroke*. 1980;11:173–177.
27. Gonner F, Remonda L, Mattle H, Sturzenegger M, Ozdoba C, Lovblad KO, Baumgartner R, Bassetti C, Schroth G. Local intra-arterial thrombolysis in acute ischemic stroke. *Stroke*. 1998;29:1894–1900.



Stroke

JOURNAL OF THE AMERICAN HEART ASSOCIATION

FINAL PROOF