
**Hemorrhagic Stroke Patient
Management in the ED:
*What are the Current Roles of
Operative Intervention and
Factor VIIa?***

William Dalsey, MD, FACEP



**2006 Advanced Emergency
& Acute Care Medicine and
Technology Conference**

William Dalsey, MD, FACEP



**Emergency Medicine
Associates**

**Atlantic City, NJ
September 26-27, 2006**

William Dalsey, MD, FACEP



William Dalsey, MD, FACEP

**Chairman
Department of Emergency Medicine
Kimball Medical Center
Lakewood, NJ**

William Dalsey, MD, FACEP




Disclosures

- All past advisory board or speakers' bureau activities have expired within the past year

William Dalsey, MD, FACEP



Case Presentation



William Dalsey, MD, FACEP



Case Presentation

- 52 year old male
- Right sided weakness one hour
- Gradual onset and progressive
- PMH: Hypertention, Smoker
- VS: HR 90 RR 14 BP 195/110

William Dalsey, MD, FACEP



Case Presentation...

- Slow to respond verbally but appropriate
 - Right sided weakness
 - Able to protect his airway
 - BGM 120mg/dl
 - No evidence of trauma or toxidrome
- What do you do now?

William Dalsey, MD, FACEP



Pathophysiology of ICH Regarding Hemorrhage Growth ?

- Intra-arterial bleeding into parenchyma
- 78-88% from chronic hypertention
- Secondary ICH: amyloid, coumadin, aneurysms, AVMs, tumors, drug use, thrombolytics
- 23-58% mortality at six months
- Half of deaths occur within 48 hs
- Only 20% living independently at 6 months

William Dalsey, MD, FACEP



Risk Factors ICH

- Hypertension
- Cerebral amyloid angiopathy
- Alcohol
- Hypocholesterolemia
- Aspirin
- Heparin, coumadin, thrombolytics
- Vascular abnormalities
- Drug abuse
- Trauma
- Intracranial surgery
- Vasculitis

William Dalsey, MD, FACEP



Pathophysiology

- Primary Injury
- Secondary Injury: Toxic effect, proteins, edema, elevation ICP, obstructive hydrocephalus

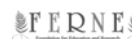William Dalsey, MD, FACEP



Prognosis/Initial Management

- Posterior Fossa vs Lobar
- GCS scores
- Size of Hemorrhage
- Early Ventricular Blood
- Supportive Management: airway, hypoxia, glucose, MAP, seizures

William Dalsey, MD, FACEP



Intracerebral Hemorrhage

- How does hemorrhage growth relate to clinical status and the ICH patient ?

William Dalsey, MD, FACEP



Intracerebral Hemorrhage

Volume of intracerebral hemorrhage. A powerful and easy-to-use predictor of 30-day mortality.

Broderick JP, Brott TG, Duldner JE, Tomsick T, Huster G. 1993 Stroke

<http://stroke.ahajournals.org/cgi/content/abstract/24/7/987>

William Dalsey, MD, FACEP



Intracerebral Hemorrhage

- Retrospective study of 188 ICH patients
- Hemorrhage volume and GCS scores
- ICH bleeding volumes $>60 \text{ cm}^3$ and GCS < 9 mortality 91%
- ICH volumes $< 30 \text{ cm}^3$ and a GCS >8 mortality 19%

William Dalsey, MD, FACEP



Intracerebral Hemorrhage

The ABC's of Measuring Intracerebral Hemorrhage

Kothari RU, Brott TG, Broderick JP et. al. Stroke 1996;27:1304-5

William Dalsey, MD, FACEP



Intracerebral Hemorrhage

- $\frac{1}{2}$ the product of the diameter of the largest bleed times the perpendicular measurement times the number of slices times the diameter of the slices

William Dalsey, MD, FACEP



Intracerebral Hemorrhage

- Early hemorrhage growth in patients with intracerebral hemorrhage.

Brott T, Broderick J, Kothari R, Barsan W, Tomsick T, Sauerbeck L, Spilker J, Duldner J, Khoury J.

- 1997 Stroke

- <http://stroke.ahajournals.org/cgi/content/full/28/1/1>

William Dalsey, MD, FACEP



Intracerebral Hemorrhage

- Prospective observational study
- CT at time zero, 1 hour and 20 hours
- In 103 patients
- In a total of 103 patients with these scans, 26% had a growth in volume > 33% by 1 hour, and 38 % had a similar growth by 20 hours
- These patients had a greater decrease in NIHSS and a greater likelihood that there would be a > 2 drop in GCS.

William Dalsey, MD, FACEP



Surgery in ICH

- What were the recommendations for Surgical Therapy of ICH established by the AHA Stroke Council in 1999?
- < 10cm³, large bleeds and GCS <4
- Cerebellar, <45 yo, structural lesions, large lobar bleeds

William Dalsey, MD, FACEP



Intracerebral Hemorrhage

Early surgery versus initial conservative treatment in patients with spontaneous supratentorial intracerebral haematomas in the International Surgical Trial in Intracerebral Haemorrhage (STICH): a randomized trial.

Mendelow AD, Gregson BA, Fernandes HM, Murray GD, Teasdale GM, Hope DT, Karimi A, Shaw MD, Barer DH; STICH investigators.
2005 Lancet

http://www.thelancet.com/journal/vol365/iss9457/abs/llan.365.9457.analysis_and_interpretation.32126.1

William Dalsey, MD, FACEP



STICH TRIAL

- Prospective randomized trial 1033 patients
- Surgery w/in 24 hs vs. medical management
- Outcome at 6 months
- Results: 23.8% favorable outcomes in the “Initial Conservative Treatment” group compared with 26.1% in the “Early Surgical Group.” These differences were not significant (odds ratio 0.89; 95% CI, 0.66-1.10). There was no difference in mortality of 36.3% with 37.4%.

William Dalsey, MD, FACEP



STICH Limitations

- Physician choice in terms of the specific procedure
- Patients were randomized only when uncertain if surgical or medical treatment was best
- In 12% of patients assigned to surgery either the surgery did not occur or it was delayed for more than 24 hours
- In patients assigned to medical treatment 26% crossed-over to surgery.

William Dalsey, MD, FACEP



ICH and Surgery 2005

- Priorities for Clinical Research in Intracerebral Hemorrhage. Report From a National Institute of Neurological Disorders and Stroke Workshop. 2005 Stroke;36:e23
- No clear benefit
- Cerebellar Hemorrhage
- Life-threatening Lobar Hemorrhage
- Future Studies

William Dalsey, MD, FACEP



ICH and Factor VIIa

- What is the role for Factor VIIa in the management of ICH patients?

William Dalsey, MD, FACEP



ICH and Factor VIIa

Safety and feasibility of recombinant factor VIIa for acute intracerebral hemorrhage.

Mayer SA, Brun NC, Broderick J, Davis S, Diringner MN, Skolnick BE, Steiner T; Europe/AustralAsia NovoSeven ICH Trial Investigators.

2005 Stroke

<http://stroke.ahajournals.org/cgi/content/abstract/36/1/74>

William Dalsey, MD, FACEP



ICH and Factor VIIa

Recombinant activated factor VII for acute intracerebral hemorrhage.

Mayer SA, Brun NC, Begtrup K, Broderick J, Davis S, Diringner MN, Skolnick BE, Steiner T; Recombinant Activated Factor VII Intracerebral Hemorrhage Trial Investigators.

2005 NEJM

<http://content.nejm.org/cgi/content/short/352/8/777>

William Dalsey, MD, FACEP



ICH and Factor VIIa

- Prospective, randomized study of 399 patients
- Three doses of recombinant factor VIIa dosed within one hour of the baseline CT
- Growth of ICH and outcomes at 90 days

William Dalsey, MD, FACEP



ICH and Factor VIIa

- Results: Improved Outcomes
29% vs 16% ICH Growth
69% vs 54% Severe Disability
28% vs 18% Mortality
- Complications: CVA, AMI 7% vs 2%

William Dalsey, MD, FACEP



ICH and Factor VIIa

- What is the role for Factor VIIa in the management of ICH patients who have an elevated INR due to warfarin use?

William Dalsey, MD, FACEP



ICH and Factor VIIa

Recombinant factor VIIa for rapid reversal of warfarin anticoagulation in acute intracranial hemorrhage.

Freeman WD, Brott TG, Barrett KM, Castillo PR, Deen HG Jr, Czervionke LF, Meschia JF.

2004 Mayo Clinic Proc

<http://www.mayoclinicproceedings.com/Abstract.asp?AID=775&Abst=Abstract&UID>

William Dalsey, MD, FACEP



Conclusions Re: Factor VIIa

- **Priorities for Clinical Research in Intracerebral Hemorrhage. Report From a National Institute of Neurological Disorders and Stroke Workshop.**
- **2005 Stroke**
- <http://stroke.ahajournals.org/cgi/content/abstract/36/3/e23>

William Dalsey, MD, FACEP



Future Research

- **Priorities for Clinical Research in Intracerebral Hemorrhage. Report From a National Institute of Neurological Disorders and Stroke Workshop. 2005 Stroke;36:e23**

William Dalsey, MD, FACEP



Guidelines for ICH Care?

- **Guidelines for the management of spontaneous intracerebral hemorrhage: A statement for healthcare professionals from a special writing group of the Stroke Council, American Heart Association.**
- Broderick JP, Adams HP Jr, Barsan W, Feinberg W, Feldmann E, Grotta J, Kase C, Krieger D, Mayberg M, Tilley B, Zabramski JM, Zuccarello M.
1999 Stroke

William Dalsey, MD, FACEP



Intracerebral Hemorrhage

- **So, what happened to my patient?**

William Dalsey, MD, FACEP



Questions?

www.FERNE.org

sparkledmd@aol.com

ferne_ema_2006_dalsey_ich_092606_final.cd
10/3/2006 5:25 PM

William Dalsey, MD, FACEP

