


Neuroimaging in the Emergency Department Patient Presenting with a Seizure


Exploring the ACEP/AAN Practice Parameter

Heather Prendergast, MD, FACEP

1

**Neuroimaging in the
Emergency Department
Patient Presenting
with a Seizure**
*Exploring the ACEP/AAN
Practice Parameter*



Heather Prendergast, MD, FACEP 


**FERNE/EMRA
Session**

**Chicago, IL
May 18, 2007**

Heather Prendergast, MD, FACEP 


Heather M. Prendergast, MD, MPH
Associate Professor

Department of Emergency Medicine
University of Illinois College of Medicine
Chicago, IL

Heather Prendergast, MD, FACEP 


Disclosures

- None


Heather Prendergast, MD, FACEP 

Key Clinical Question

- What is the optimal clinical approach to neuroimaging a seizure patient based on the ACEP practice parameter?

Heather Prendergast, MD, FACEP 

A Clinical Case

Heather Prendergast, MD, FACEP 

Patient EMS Data

- 63 yo male
- First time Generalized tonic-clonic seizure witnessed by spouse
- Chicago Fire Department
- Post-ictal on arrival of EMS
- EMS to ED

Heather Prendergast, MD, FACEP



Patient Clinical History

- Meds: Accupril, Sildenafil
- Pmhx: Hypertension, Sexual Dysfunction
- Social Hx: no tobacco, EtOH , or illicit drug use
- Married

Heather Prendergast, MD, FACEP



ED Presentation

- Awake, alert and oriented
- Normal vital signs
- Neurologically intact
- Bedside Glucose 119

Heather Prendergast, MD, FACEP



Why Consider This Case?

- First time seizure
- Few hospitals utilize a seizure protocol
- Protocol improves patient outcome
- Guidelines exist that facilitate practice

Heather Prendergast, MD, FACEP



Practice Parameter

Heather Prendergast, MD, FACEP



Recommendation Strength

- Standards: High degree of clinical certainty
- Guidelines: Management Strategies
- Practice Parameters: Specific recommendations from a scientifically based analysis

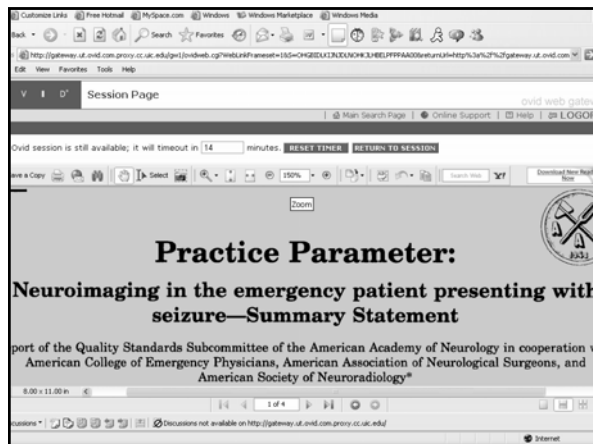
Heather Prendergast, MD, FACEP



Joint Project

- American College of Emergency Physicians (ACEP)
- American Academy of Neurology (AAN)
- American Association of Neurological Surgeons (AANS)
- American Society of Neuroradiology (ASN)

Heather Prendergast, MD, FACEP



Methods

- MEDLINE search
- Primary modality : CT
- Excluded Status Epileptics

Heather Prendergast, MD, FACEP



Data Elements

- Age Stratification
- Likelihood of abnormal CT
- Types of CT lesions
- Outcome data

Heather Prendergast, MD, FACEP



Co-variables

- First Seizure
- Seizure Type
- Signs of CNS infection
- Persistent altered mental status
- Recent trauma

Heather Prendergast, MD, FACEP



Co-variables

- Meningismus
- New Focal Abnormality
- History of anticoagulation
- Immunosuppression
- Malignancy
- Headache

Heather Prendergast, MD, FACEP



Consensus : Need and Urgency of Neuroimaging

- **Emergent:** Timely decision for potentially life-threatening entities
- **Urgent :** Timely appropriate clinical disposition
- **Routine:** Indicated for management but not disposition

Heather Prendergast, MD, FACEP



Evidence Levels

- **Class I:** Randomized controlled clinical trials,
- **Class II:** Clinical Studies (Case-control, Cohort)
- **Class III:** Expert opinion, case report

Heather Prendergast, MD, FACEP



Practice Parameter: Recommendations Neuroimaging

- **Usefulness**



- **Timing**



- **Utility**



Heather Prendergast, MD, FACEP



First Time Seizure

- **Emergent Neuroimaging:**
 - Suspect structural lesion
 - New focal deficits, Persistent altered mental status, fever, trauma, headache, cancer, anticoagulation, HIV/AIDS
 - Age over 40
 - Partial-onset seizure

Heather Prendergast, MD, FACEP



First Time Seizure

- **Urgent Neuroimaging:**
 - Completed recovered & no identifiable cause
 - Hypoglycemia
 - Hyponatremia
 - TCA overdose

Heather Prendergast, MD, FACEP



Epilepsy with Recurrent Seizure (s)

- **Emergent Neuroimaging :**
 - Suspect structural lesion
 - New focal deficits, Persistent altered mental status, fever, trauma, headache, cancer, anticoagulation, HIV/AIDS
 - New seizure type or pattern
 - Prolonged postictal confusion
 - Worsened mental status

Heather Prendergast, MD, FACEP



Epilepsy with Recurrent Seizure (s)

- **Urgent Neuroimaging:**
 - Completed recovered & no identifiable cause
 - Hypoglycemia
 - Hyponatremia
 - TCA overdose

Heather Prendergast, MD, FACEP



Febrile Seizure

- **Unlikely to have structural lesion**
- **Emergent or Urgent NI not indicated**

Heather Prendergast, MD, FACEP

