



**Advances in CT
Technology:**
*Implications for the Diagnosis
and Treatment of Stroke*

Stephen Huff, MD



Stephen Huff, MD
Associate Professor
**Department of Emergency Medicine
University of Virginia**


Stephen Huff, MD



Disclosures

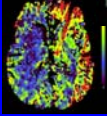
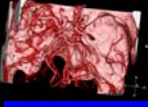
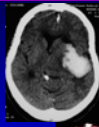
- Executive Board, Foundation for Education and Research in Neurologic Emergencies

Stephen Huff, MD




CTA and CTP

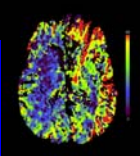
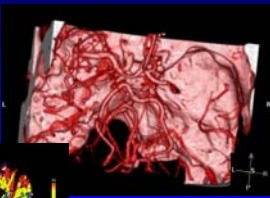
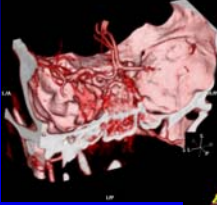
- Essential questions
 - Is there hemorrhage?
 - Is there a stroke?
 - Is there large vessel occlusion?
 - Is there "irreversibly" infarcted core?
 - Is there "at risk" penumbra?
- One contrast bolus yields two datasets
 - Vessel patency
 - Infarct versus salvageable penumbra




Stephen Huff, MD



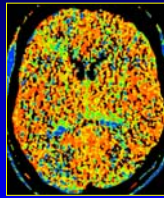
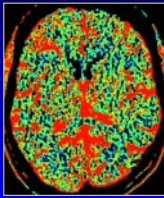
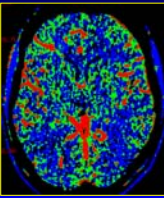
CT Angio & Perfusion



Stephen Huff, MD




CT Perfusion Terminology



Blood Flow Blood Volume Mean Transit Time
or
Time to Peak


Stephen Huff, MD



FERNE / EMRA 2007 Acute Ischemic Stroke Patients :
Advances in CT Technology: Implications for the Diagnosis and Treatment of Stroke
Stephen Huff, MD, FACEP


Definitions

Perfusion	The steady-state delivery of blood to cerebral tissue through the capillaries
Cerebral Blood Flow (CBF)	Volume flow rate of blood through the cerebral vasculature per unit time
Cerebral Blood Volume (CBV)	Amount of blood in a given amount of tissue at any time
Mean Transit Time (MTT)	Average time it takes for blood to traverse from the arterial to the venous side of the cerebral vasculature

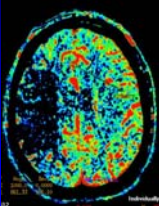
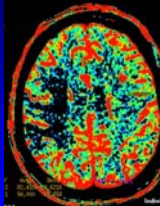
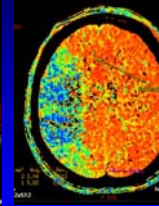
Stephen Huff, MD 

Changes in Cerebral Vascular Physiology with Worsening Circulatory Impairment


	CBF	CBV	MTT
Salvageable Penumbra	↓	↑	↑
Irretrievable Infarct	↓	↓	↑↑

Stephen Huff, MD 


Relationship between CBV, CBF, and MTT

Blood Flow Blood Volume Mean Transit Time
 or
 $MTT = \text{Blood Flow} / \text{Blood Volume}$ Time to Peak


Stephen Huff, MD 

Case: Value of CTA/CTP within 3 hour window





- 50 yo male
- CT within hour of symptom onset
- Awake, alert, dysarthric
- Fixed right sided gaze
- Left sided weakness

Initial













Stephen Huff, MD 

Case: Value of CTA/CTP within 3 hour window




Stephen Huff, MD 

Case: Value of CTA/CTP within 3 hour window

Initial BF BV TTP

Stephen Huff, MD 

FERNE / EMRA 2007 Acute Ischemic Stroke Patients :
Advances in CT Technology: Implications for the Diagnosis and Treatment of Stroke
Stephen Huff, MD, FACEP

Case:
Value of CTA/CTP within 3 hour window

Initial BF BV TTP 3 day fu

Stephen Huff, MD

Case:
"Wake up" Stroke

0735 at outside hospital

Stephen Huff, MD

Case:
"Wake up" Stroke

Stephen Huff, MD

Case:
"Wake up" Stroke

1030 at stroke center

Stephen Huff, MD

Case:
"Wake up" Stroke

24 hours later at stroke center

Stephen Huff, MD

Conclusions

- CTA identifies an occlusive lesion
- Core infarct (not reversible):
 Poor blood flow and blood volume with extremely long transit time
- Ischemic penumbras (reversible):
 Poor blood flow with increased blood volume and some increase in transit time
- CTA can distinguish these two
- Perhaps IV tPA use can be optimized
- Standard: give IV tPA if within 3 hours

Stephen Huff, MD

**FERNE / EMRA 2007 Acute Ischemic Stroke Patients :
Advances in CT Technology: Implications for the Diagnosis and Treatment of Stroke
Stephen Huff, MD, FACEP**

Questions?

J. Stephen Huff
huff@virginia.edu

www.ferne.org

ferne_sims_2007_caseconf_huff_cta_100907_finalcd
10/18/2007 10:45 AM

Stephen Huff, MD

