


***Advances in CT
 Technology:
 Implications for the Diagnosis
 and Treatment of Stroke***

Stephen Huff, MD 

Stephen Huff, MD


Associate Professor

**Department of Emergency Medicine
 University of Virginia**

Stephen Huff, MD 

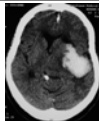
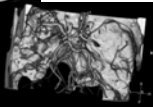
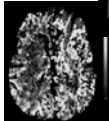
Disclosures


- Executive Board, Foundation for Education and Research in Neurologic Emergencies

Stephen Huff, MD 

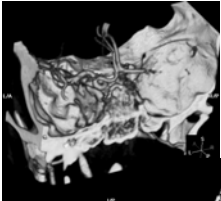
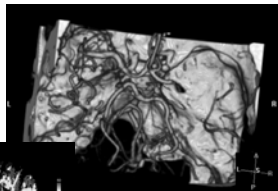
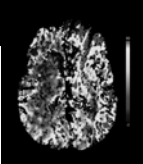
CTA and CTP


- Essential questions
 - Is there hemorrhage?
 - Is there a stroke?
 - Is there large vessel occlusion?
 - Is there “irreversibly” infarcted core?
 - Is there “at risk” penumbra?
- One contrast bolus yields two datasets
 - Vessel patency
 - Infarct versus salvageable penumbra

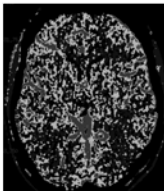
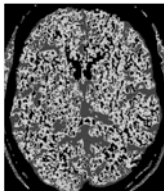
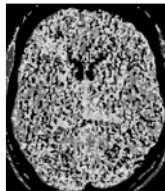
Stephen Huff, MD 

CT Angio & Perfusion






Stephen Huff, MD 

CT Perfusion Terminology


**Blood Flow Blood Volume Mean Transit Time
 or
 Time to Peak**

Stephen Huff, MD 

FERNE / EMRA 2007 Acute Ischemic Stroke Patients :
Advances in CT Technology: Implications for the Diagnosis and Treatment of Stroke
Stephen Huff, MD, FACEP


Definitions

Perfusion	The steady-state delivery of blood to cerebral tissue through the capillaries
Cerebral Blood Flow (CBF)	Volume flow rate of blood through the cerebral vasculature per unit time
Cerebral Blood Volume (CBV)	Amount of blood in a given amount of tissue at any time
Mean Transit Time (MTT)	Average time it takes for blood to traverse from the arterial to the venous side of the cerebral vasculature

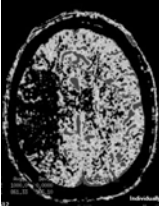
Stephen Huff, MD 

Changes in Cerebral Vascular Physiology with Worsening Circulatory Impairment

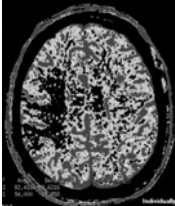
	CBF	CBV	MTT
Salvageable Penumbra	↓	↑	↑
Irretrievable Infarct	↓	↓	↑↑

Stephen Huff, MD 

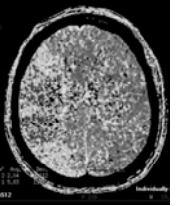
Relationship between CBV, CBF, and MTT



Blood Flow




Blood Volume

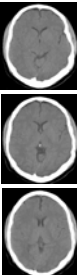


Mean Transit Time

or
 $MTT = \frac{\text{Blood Volume}}{\text{Blood Flow}}$ Time to Peak


Stephen Huff, MD 

Case: Value of CTA/CTP within 3 hour window

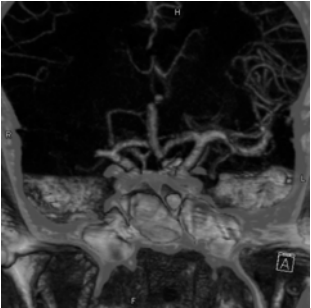



Initial

- 50 yo male
- CT within hour of symptom onset
- Awake, alert, dysarthric
- Fixed right sided gaze
- Left sided weakness

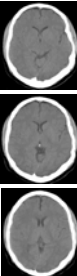
Stephen Huff, MD 

Case: Value of CTA/CTP within 3 hour window

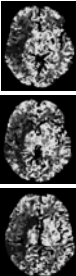


Stephen Huff, MD 

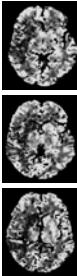
Case: Value of CTA/CTP within 3 hour window




Initial




BF



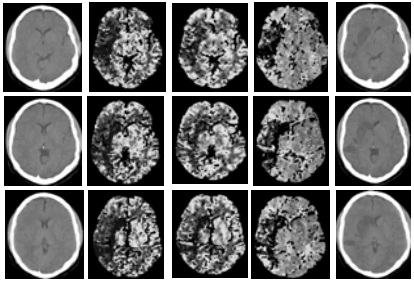
BV




TTP

Stephen Huff, MD 

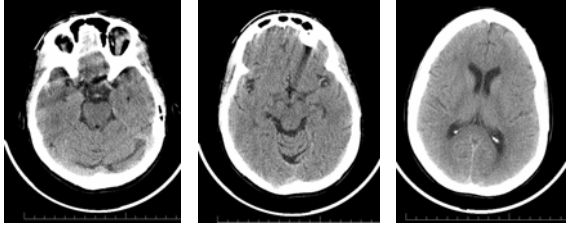
Case:
Value of CTA/CTP within 3 hour window




Initial BF BV TTP 3 day fu

Stephen Huff, MD 

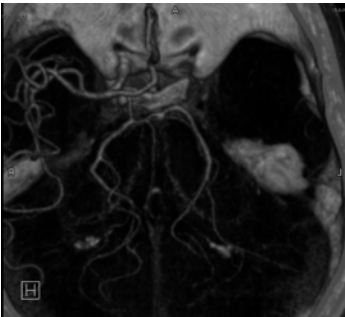
Case:
“Wake up” Stroke




0735 at outside hospital

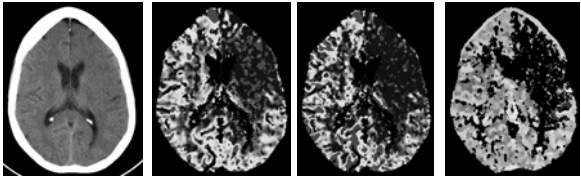
Stephen Huff, MD 

Case:
“Wake up” Stroke




Stephen Huff, MD 

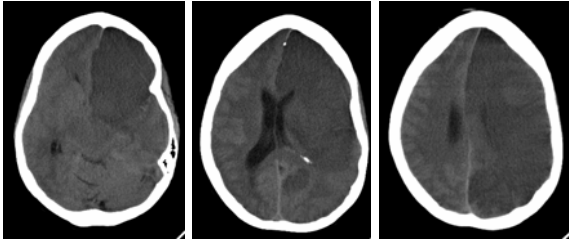
Case:
“Wake up” Stroke




1030 at stroke center

Stephen Huff, MD 

Case:
“Wake up” Stroke




24 hours later at stroke center

Stephen Huff, MD 

Conclusions

- CTA identifies an occlusive lesion
- Core infarct (not reversible):
 Poor blood flow and blood volume with extremely long transit time
- Ischemic penumbras (reversible):
 Poor blood flow with increased blood volume and some increase in transit time
- CTA can distinguish these two
- Perhaps IV tPA use can be optimized
- Standard: give IV tPA if within 3 hours

Stephen Huff, MD 

**FERNE / EMRA 2007 Acute Ischemic Stroke Patients :
Advances in CT Technology: Implications for the Diagnosis and Treatment of Stroke
Stephen Huff, MD, FACEP**

Questions?

**J. Stephen Huff
*huff@virginia.edu***

www.ferne.org

ferne_emra_2007_caseconf_huff_cta_100907_finalcd
10/18/2007 10:46 AM

Stephen Huff, MD

