

The Diagnosis of SAH in ED Headache Patients: What Roles for CT Neuroimaging and Lumbar Puncture?

E. Bradshaw Bunney, MD, FACEP 

E. Bradshaw Bunney, MD

Associate Professor
Department of Emergency Medicine
University of Illinois at Chicago
Our Lady of the Resurrection Medical Center
Chicago, IL

E. Bradshaw Bunney, MD, FACEP 

Disclosures

- AstraZeneca, advisory board
- Genentech, speakers bureau
- ACEP Scientific Review Committee
- Executive Board, Foundation for Education and Research in Neurologic Emergencies

E. Bradshaw Bunney, MD, FACEP 

Objectives

- Improve screening of patients for SAH
- Learn key points in diagnosis, treatment disposition, documentation
- Improve outcome of patients with SAH
- Further Emergency Medicine practice as it relates to SAH

E. Bradshaw Bunney, MD, FACEP 

A Clinical Case

E. Bradshaw Bunney, MD, FACEP 

Patient Clinical History

- 47 yo female
- Shopping with her husband
- Severe, sudden onset of headache
- Sat down → passed out for 3-5 minutes
- Hx of HTN on diuretic

E. Bradshaw Bunney, MD, FACEP 

ED Presentation

- Vitals: 99.5F, 105, 16, 190/95, 98% RA
- Lying still on stretcher with eyes closed
- NCAT, Heart, lungs, abdomen normal
- “Sore” neck, no clear meningismus
- Alert, mild confusion
- CN intact, strength 5/5 all 4 ext, sensory intact, DTRs normal, FTN normal

E. Bradshaw Bunney, MD, FACEP 

Critical Questions

- Who is at risk for SAH?
- What symptoms suggest SAH?
- How can we best diagnose SAH?
- Who requires CT? LP? Angiography?
- When should an LP be deferred?
- When is “traumatic tap” the likely diagnosis?
- When does symptom resolution suggest a benign headache etiology?

E. Bradshaw Bunney, MD, FACEP 

SAH Epidemiology

- 5% of all strokes
- < 1% of all headaches
- 50% mortality if not diagnosed
- Large risk of litigation

E. Bradshaw Bunney, MD, FACEP 

SAH Epidemiology

- Majority are traumatic
- Non-traumatic
 - 50% aneurysmal
 - 15% hypertension
 - 6% AVM

E. Bradshaw Bunney, MD, FACEP 

SAH Presentation

- 85% Headache
- 40% Nausea and vomiting
- Only 15% meningeal signs

E. Bradshaw Bunney, MD, FACEP 

SAH Headache

- New type of headache
- Worst headache of life
- Thunderclap – immediate maximal intensity
- Warning headache
 - Sentinel bleed
 - 15-40% of SAH patients
 - Typically occur 2 weeks prior to SAH

E. Bradshaw Bunney, MD, FACEP 

“Worst Headache of My Life”

- N= 107 patients “worst headache”
- 20 pts with SAH (19.5%)
- 18 of 20 diagnosed by CT (90%)
- Two diagnosed: + LP after - CT
- NPV of CT = $87/89 = 98\%$
(2% would have SAH)

E. Bradshaw Bunney, MD, FACEP 

“Worst Headache” LP Results

- Positive LP, Negative CT (n=2)
 - Tube 1 RBCs: 163,000 median
 - Tube 4 RBCs: 221,000 median
- Negative LP, Negative CT (N = 77)
 - Tube 1 RBCs: 19 median
 - Tube 4 RBCs: 0 median

E. Bradshaw Bunney, MD, FACEP 

SAH: *The Evaluation*

E. Bradshaw Bunney, MD, FACEP 

SAH: Risk Stratification

- Female
- Age > 50
- Exertion
- Hypertension
- Smoking
- Altered consciousness
- Neurological deficit
- Type of headache

E. Bradshaw Bunney, MD, FACEP 

SAH: Diagnostic Tests

- CT scan
- MRI
- Lumbar puncture
- Angiography

E. Bradshaw Bunney, MD, FACEP 

SAH: CT Scan

- Most available
- Fast
- Most studied
- Depend on several factors
 - Type of scanner
 - Time since bleeding began
 - Size of the bleed
 - Experience of the radiologist

E. Bradshaw Bunney, MD, FACEP 

SAH: CT Scan

- Sensitivity approaches 100% in 5th generation CT scanners
 - 3 mm thickness through base of the brain
- Within the first 12 hours
- 93-95% > 12 hours
- Inform the radiologist about possibility of SAH

E. Bradshaw Bunney, MD, FACEP 

SAH: The Evaluation

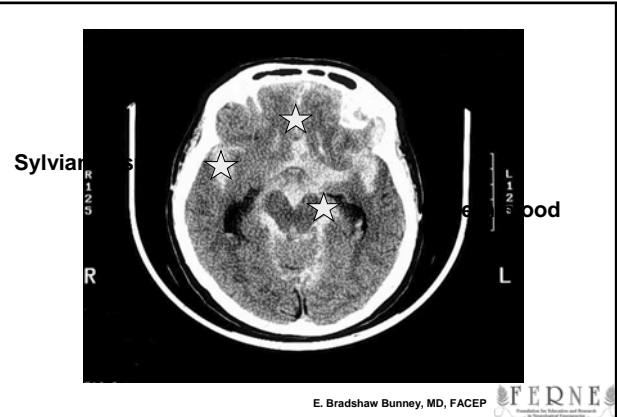
- How do we evaluate a CT for SAH?

E. Bradshaw Bunney, MD, FACEP 

SAH: CT Interpretation

- CT evaluation for subarachnoid blood
 - 1) Inter-hemispheric fissure
 - 2) Inferior frontal sulci
 - 3) Third ventricle
 - 4) Ambient cistern
 - 5) Sylvian fissure

E. Bradshaw Bunney, MD, FACEP 



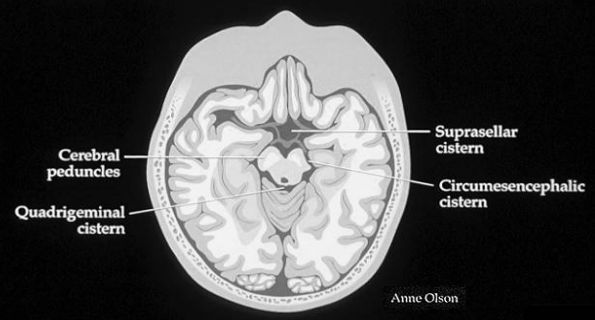
E. Bradshaw Bunney, MD, FACEP 

CT Interpretation: Elevated ICP

- CT findings that exclude elevated ICP
 - Normal cisterns
 - No obliteration of cistern space
 - No edema, mass effect, or midline shift
 - No hydrocephalus

E. Bradshaw Bunney, MD, FACEP 

2. Cisterns Viewed at Level of Cerebral Peduncles



E. Bradshaw Bunney, MD, FACEP 

Symptom Resolution

- Can headache resolution be used to exclude SAH?
- Brings to mind another question....
In a patient who presents to the ED with a headache, can you rule out SAH by clinical evaluation alone?

E. Bradshaw Bunney, MD, FACEP 

Symptom Resolution

Consider headaches likely benign if:

- Low risk SAH patient
- No focal neurological findings
- Complete symptom resolution with meds that effectively treat migraine and muscle-tension headache (i.e. non-narcotic)
- Headache similar to prior headaches

E. Bradshaw Bunney, MD, FACEP 

Lumbar Puncture Need

Which patients should have a lumbar puncture?

E. Bradshaw Bunney, MD, FACEP 

Lumbar Puncture Indications

- Moderate to high risk SAH patients following negative CT
- Severe, abrupt, thunderclap headache
- Focal neurological findings
- Unknown CT protocol / interpretive quality
- Minimal symptom resolution with meds that effectively treat migraine and muscle-tension headache

E. Bradshaw Bunney, MD, FACEP 

Deferred Lumbar Puncture

- Is it sometimes reasonable to not perform a lumbar puncture on patients suspected of SAH?

E. Bradshaw Bunney, MD, FACEP 

Deferred Lumbar Puncture

- Positive CT
 - Evidence of elevated ICP, edema, mass effect, midline shift, ICH, hydrocephalus
- Technically difficult procedure
- Critically ill or unstable patient
- Coagulopathy

E. Bradshaw Bunney, MD, FACEP 

SAH: The Evaluation

- How should we interpret CSF results?

E. Bradshaw Bunney, MD, FACEP 

Interpreting CSF: RBCs

- Likely SAH with:
 - 10,000-100,000 RBCs or greater
 - No clearing of RBCs in tube 4
- Consider possible SAH with:
 - Intermediate RBC count (1,000 – 10,000)
 - Little RBC clearing by tube 4
- Traumatic tap
 - 75-90% drop in RBCs from tube 1 to 4

E. Bradshaw Bunney, MD, FACEP 

CSF Xanthochromia

- Xanthochromia characteristics
 - Typically > 12 hours from headache onset
 - Quantitative and qualitative measurements
 - “Read news print test” most often used
 - Clears after weeks
 - Oxyhemoglobin = pink, bilirubin = yellow

E. Bradshaw Bunney, MD, FACEP 

SAH: The Evaluation

- When is angiography indicated?

E. Bradshaw Bunney, MD, FACEP 

SAH: Cerebral Angiography

- Cerebral angiography indications:
 - High risk patients with uncertain diagnosis
 - Interventional radiology available for coiling
 - Preoperative neurosurgical planning
- MRI, MRA, CTA need less well established

E. Bradshaw Bunney, MD, FACEP 

SAH: MRI

- MRI classically not good at detecting blood
- Take longer
- Claustrophobia
- Not available

E. Bradshaw Bunney, MD, FACEP 

SAH: MRI

- FLAIR – Fluid-attenuated Inversion Recovery
 - Detects increase in CSF cellularity and protein
- Da Rocha et al. 100% sensitive at detecting SAH up to 15 days after bleed
- CT scan 66% sensitive
- Small N = 45

E. Bradshaw Bunney, MD, FACEP 

Treating SAH

E. Bradshaw Bunney, MD, FACEP 

Treating SAH Patients

- SAH with increased ICP:
 - Head of the bed at 35 degrees
 - Mannitol 20% solution 0.25-1.0g per Kg
 - Hyperventilation to pCO₂ 30-35 mmHg, temporizing, only if other measures fail
 - Ventriculostomy
 - Consider seizure prophylaxis
 - Nimodopine (vasoconstriction prophylaxis)

E. Bradshaw Bunney, MD, FACEP 

Headache in the ED: Evidence-based Recommendations

E. Bradshaw Bunney, MD, FACEP 

Grading of Recommendations

Level A recommendations. Generally accepted principles for patient management that reflect a high degree of clinical certainty (ie, based on “strength of evidence class I” or overwhelming evidence from “strength of evidence class II” studies that directly address all the issues).

Level B recommendations. Recommendations for patient management that may identify a particular strategy or range of management strategies that reflect moderate clinical certainty (ie, based on “strength of evidence class II” studies that directly address the issue, decision analysis that directly addresses the issue, or strong consensus of “strength of evidence class III” studies).

Level C recommendations. Other strategies for patient management that are based on preliminary, inconclusive, or conflicting evidence or, in the absence of any published literature, based on panel consensus.

E. Bradshaw Bunney, MD, FACEP 

ACEP Policy: Acute Headache

- Does a response to therapy predict the etiology of an acute headache?
 - Level C:
 - Pain response to therapy should not be used as the sole diagnostic criteria in determining the underlying etiology of an acute headache.

E. Bradshaw Bunney, MD, FACEP 

ACEP Policy: Acute Headache

- In which adults with a headache can an LP be safely performed without neuroimaging?
 - Level C:
 - Those pts without signs of increased intracranial pressure (ICP)
 - Papilledema, absent venous pulses
 - Altered mental status
 - Focal neurologic deficits

E. Bradshaw Bunney, MD, FACEP 

ACEP Policy: Acute Headache

- Which patients with an acute headache require neuroimaging?
 - Level B:
 - Headache and focal neurologic deficit
 - Headache of sudden, rapid onset (e.g. SAH)
 - HIV and new headache
 - Level C:
 - > 50 years old, new or different headache

E. Bradshaw Bunney, MD, FACEP 

ACEP Policy: Acute Headache

- Do patients with “thunderclap” headache need an angiogram after a negative CT and LP?
 - Level C:
 - No, outpatient follow-up if:
 - Negative CT, normal opening pressure, and “negative” CSF analysis

E. Bradshaw Bunney, MD, FACEP 

ED Case Patient Outcome

E. Bradshaw Bunney, MD, FACEP 

ED Patient Management

- Pt had a generalized tonic-clonic seizure
- Responded to benzodiazepines
- Return to normal mental status

E. Bradshaw Bunney, MD, FACEP 

ED Diagnostic Evaluation

- Non-contrast CT negative
- Metabolic, toxicology tests normal
- CSF:
 - Tube 1 = 355,000 RBCs
 - Tube 4 = 298,000 RBCs
- Diagnosis: Subarachnoid Hemorrhage

E. Bradshaw Bunney, MD, FACEP 

Patient Outcome

- Cerebral angiogram performed
- Saccular aneurysm in the posterior communicating artery
- Neurosurgical aneurysm clipping
- Pt was discharged in one week
- No residual neurological deficit

E. Bradshaw Bunney, MD, FACEP 

Key Learning Points

- SAH needs to be thought of to be diagnosed
- Resolution of symptoms does not exclude SAH in all patients
- Know the CT technology where you work to be comfortable with the need for LP
- When in doubt do the LP

E. Bradshaw Bunney, MD, FACEP 

Questions??

Brad Bunney
bbunney@uic.edu
312-413-7484
www.ferne.org

ferne_eusem_2006_bunney_sah_111006_finalcd
11/13/2006 10:34 AM

E. Bradshaw Bunney, MD, FACEP 