

Diagnostic and Therapeutic Options for Emergency Stroke Care: Perspectives from the US, Italy, and Developing Countries

Andrew W. Asimos, MD
Director of Emergency Stroke Care, Carolinas Medical Center
Charlotte, NC, USA
Adjunct Associate Professor, Department of Emergency Medicine
University of North Carolina School of Medicine at Chapel Hill

Anna Maria Ferrari
Director of Emergency Department
Reggio Emilia, Italy

Junaid A. Razzak
Associate Professor and Head, Section of Emergency Medicine
Department of Medicine
Aga Khan University
Karachi, Pakistan

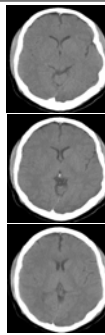
Disclosure

- Research funding from Boehringer Ingelheim Pharmaceuticals, Inc.
- Served on Emergency Medicine Advisory Board for Novo Nordisk Inc.
- Brief mention of off label use of approved devices

My Objectives

- Overview of therapeutic options in the setting of acute ischemic stroke
 - IV tPA
 - IA tPA
 - Endovascular treatment with thrombectomy devices
- Overview of diagnostic options in the setting of acute stroke
 - CTA/CTP

Acute Stroke Case



- 50 yo male
- Awake, alert, dysarthric
- Fixed right sided gaze
- Left sided weakness
- Neglect of left hemispace
- CT less than 2 hours within symptom onset

Diagnosis & Treatment Options

- What is the presumptive diagnosis?
- What are the treatment options?
- Can advanced neuroimaging be used to help guide treatment options?

Cerebrovascular
Diseases

Special Article

Cerebrovasc Dis 2003;16:311-337
DOI: 10.1198/00072554

Received June 1, 2003
Accepted July 10, 2003

European Stroke Initiative Recommendations for Stroke Management – Update 2003

The European Stroke Initiative Executive Committee and
the EUSI Writing Committee

AHA/ASA Guideline

Guidelines for the Early Management of Adults With Ischemic Stroke

A Guideline From the American Heart Association/
American Stroke Association Stroke Council, Clinical Cardiology
Council, Cardiovascular Radiology and Intervention Council, and the
Atherosclerotic Peripheral Vascular Disease and Quality of Care
Outcomes in Research Interdisciplinary Working Groups

Adams HP et al. *Stroke* 2007;38:1655-1711.
EUSI Writing Committee. *Cerebrovasc Dis* 2003;16:311-337.

IV tPA Recommendations

- **American Stroke Association**
 - Intravenous rTPA (0.9 mg/kg, maximum dose 90 mg) is recommended for selected patients who may be treated within 3 hours of onset of ischemic stroke
- **European Stroke Initiative**
 - The benefit from the use of IV tPA for acute ischemic stroke beyond 3 hours after onset of symptoms is smaller, but present up to 4.5 hours

Adams HP et al. *Stroke* 2007;38:1655-1711.
EUSI Writing Committee. *Cerebrovasc Dis* 2003;16:311-337.

SITS-MOST

Lancet 2007; 369: 275-82

Articles

Thrombolysis with alteplase for acute ischaemic stroke in the Safe Implementation of Thrombolysis in Stroke-Monitoring Study (SITS-MOST): an observational study

Nils Wahlgren, Muzi Alamej, Antoni Davalos, Gory A. Ford, Martin Gray, Werner Hacke, Michael C. Monoranji, Mariko Kuroki, Sanjay K. Ravin, Vincent Lamsy, Kennedy R. Lees, Rita O'Boine, Leon Soinne, David Fox, Gert W. Hoozemans for the SITS-MOST investigators

- 6,483 patients
- 285 centers
 - Little prior experience with thrombolysis for stroke in half
- 14 countries

SITS-MOST

	SITS-MOST Proportion (events/total; 95% CI)	Pooled randomised controlled trials* Proportion (events/total; 95% CI)
SICH per Cochrane/ NINDS definition†	7.3% (468/6438; 6.7-7.9)	8.6% (6.3-11.6)
Mortality within 3 months	11.3% (701/6218; 10.5-12.1)	17.3% (83/479; 14.1-21.1)
Independence (modified Rankin score 0-2) at 3 months	54.8% (3362/6136; 53.5-56.0)	49.0% (227/463; 44.4-53.6)

Wahlgren N et al. *Lancet* 2007;369:275-82.

Essential Imaging Questions

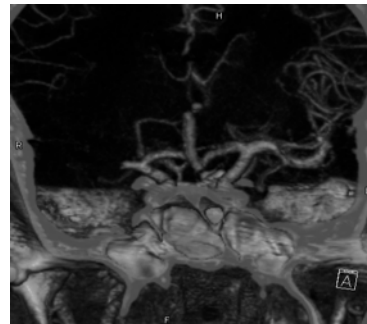
- Is there hemorrhage?
- Are findings consistent with acute ischemic stroke?
- Is there large vessel occlusion?
- Is there “irreversibly” infarcted core?
- Is there “salvageable” penumbra?
- Are other findings present that should be considered
 - Microbleeds
 - Leukoaraiosis

Imaging Recommendations

- **American Stroke Association**
 - Multimodal CT and MRI may provide additional information that will improve diagnosis of ischemic stroke
- **European Stroke Initiative**
 - Vascular imaging (ultrasound, CTA and MRA) in the acute condition gives additional information about the vessel patency in the brain and neck vessels and should supplement all imaging procedures already in the acute phase

Adams HP et al. *Stroke* 2007;38:1655-1711.
EUSI Writing Committee. *Cerebrovasc Dis* 2003;16:311-337.

Acute Stroke Case: CTA



Editorial

**Intravenous or Intra-Arterial Thrombolysis?
It's Time to Find the Right Approach for the Right Patient**

Heinrich P. Mattle

**Debunking 7 Myths That Hamper the Realization of
Randomized Controlled Trials on Intra-Arterial
Thrombolysis for Acute Ischemic Stroke**

Alfonso Ciccone, MD; Luca Valvassori, MD; Roberto Gasparotti, MD; Francesco Scomazzoni, MD;
Elena Ballabio, MD; Roberto Sterzi, MD

Stroke 2007;38

COMBATSTROKE

Home Join Us Contact Us search

CombatStroke

Home Project summary

PROJECT SUMMARY

COMBATSTROKE (Collaborative European Multi-center Basic Science and Clinical Approach in the Treatment of Stroke) combines the expertise of leading European stroke centers to address two main issues:

Leading European stroke centres will compare safety and efficacy of IV thrombolysis versus endovascular treatment of acute stroke in the anterior circulation in a randomised trial. The results from this project will give new insights in the state of the art of acute stroke treatment and have the potential to prevent dead and disability in many patients.

Large Vessel Occlusions

- Only 6-30% major vessel occlusions recanalize with IV tPA
 - 50-85% with IA tPA
- Mortality alone
 - ICA 40-70%
 - M1 25-30%
 - Basilar 80-90%
- In Multi MERCI, only 10% good outcome if not recanalized versus 50% if recanalized
 - 50% dead at 90 days if not recanalized

Outcomes of Intracranial ICA Occlusion in MERCI & Multi-MERCI I

	mRS 0-2	mRS 3	mRS 4-5	Dead
Recanalized	39%	12%	18%	31%
Non-recanalized	3%	10%	13%	73%

- 80 pts
- NIHSS 20 ± 5
- SICH 10%

Flint AC, International Stroke Conference 2007, San Francisco

Enhancement of IV tPA

- Combined IV/IA tPA plus endovascular ultrasound (IMS III trial)
- Combined IV tPA plus perflutren microbubbles given IV and extracorporeal ultrasound (ImaRx trial)
- tPA plus IIb/IIIa platelet receptor blocker (CLEAR and ROSIE trials)
- tPA plus neuroprotectives (FAST-MAG, hypothermia pilot trials, caffeine)
- tPA plus antithrombin molecule (Argatroban)

IA Recommendations

- American Stroke Association
 - IA thrombolysis is an option for treatment of selected patients who have major stroke of <6 hours duration due to occlusions of the MCA and who are not otherwise candidates for IV rTPA
 - The availability of IA thrombolysis should generally not preclude the IV administration of rTPA in otherwise eligible patients
- European Stroke Initiative
 - IA treatment of acute MCA occlusion in a 6-hour time window using pro-UK results in a significantly improved outcome
 - Acute basilar occlusion may be treated with IA therapy in selected centres in an institutional protocol as experimental therapy or within a multicentre clinical trial

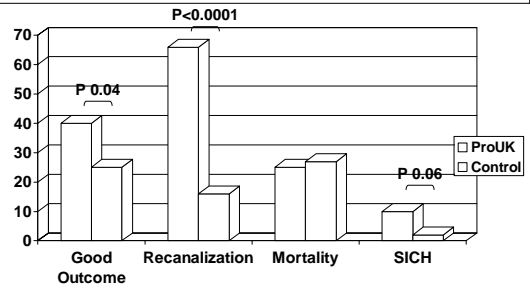
Adams HP et al. *Stroke* 2007;38:1655-1711.
EUSI Writing Committee. *Cerebrovasc Dis* 2003;16:311-337.

PROACT II

- Phase III, controlled, open-treatment trial
- MCA strokes, onset to txt < 6 hrs
- 2/3 treated with pro-UK (121)
- 1/3 treated with placebo (59)
- IV heparin: 2000 U bolus + 500 U/hr
- > 1/3 MCA change on CT excluded

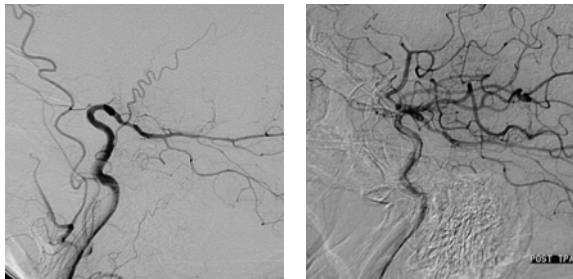
Furlan A. JAMA. 1999;282:2003-2011.

PROACT II Clinical Outcomes



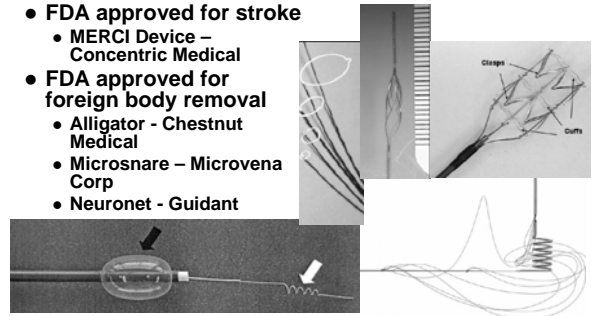
Furlan A. JAMA. 1999;282:2003-2011.

Pre- and Post t-PA



Mechanical Treatment: Thrombectomy Devices

- FDA approved for stroke
 - MERCI Device – Concentric Medical
- FDA approved for foreign body removal
 - Alligator - Chestnut Medical
 - Microsnare – Microvena Corp
 - Neuronet - Guidant



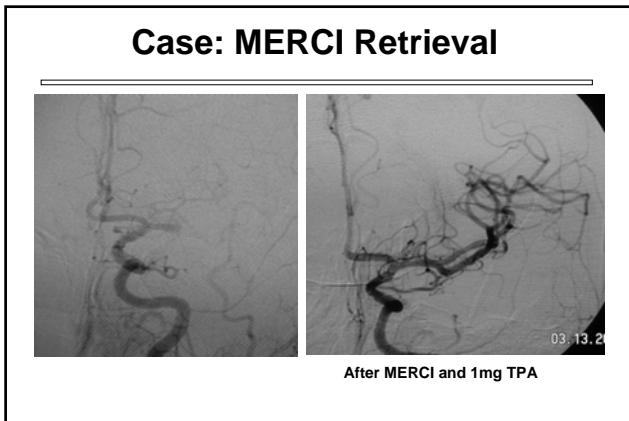
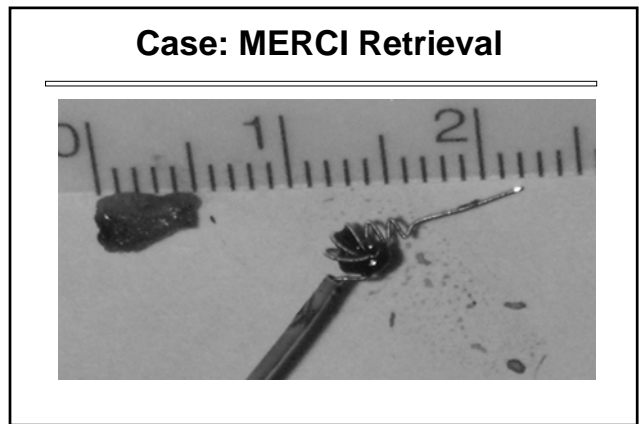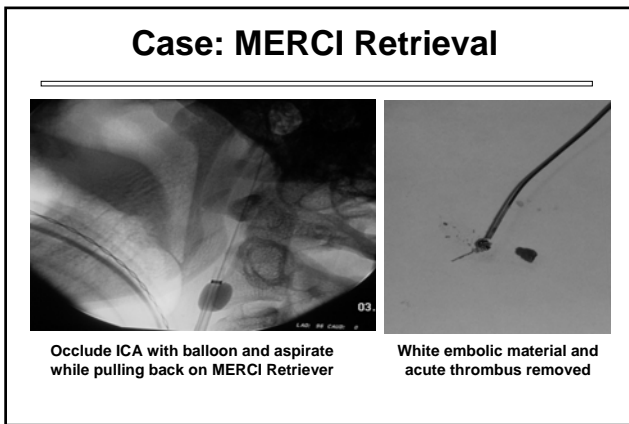
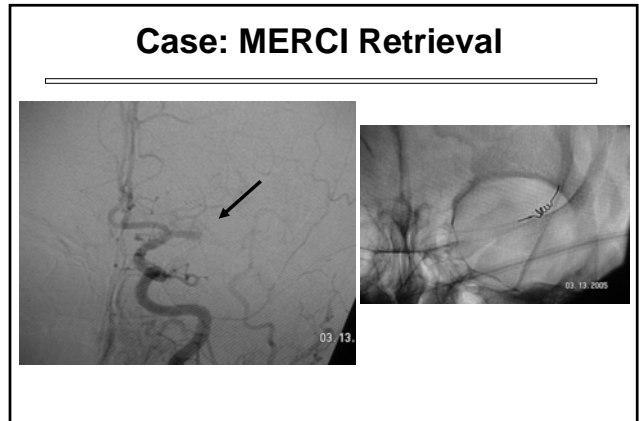
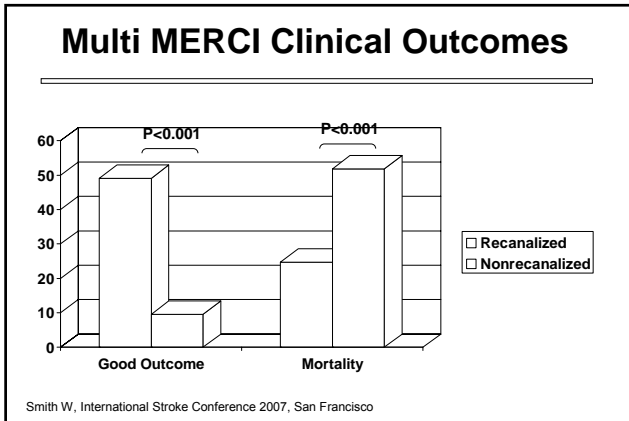
Endovascular Treatment Recommendations

- American Stroke Association
 - Although the MERCI device is a reasonable intervention for extraction of intra-arterial thrombi in carefully selected patients, the utility of the device in improving outcomes after stroke is unclear
 - The panel recommends that the device be studied in additional clinical trials that will define its role in the emergency management of stroke

Adams HP et al. Stroke 2007;38:1655-1711.

Multi- MERCI

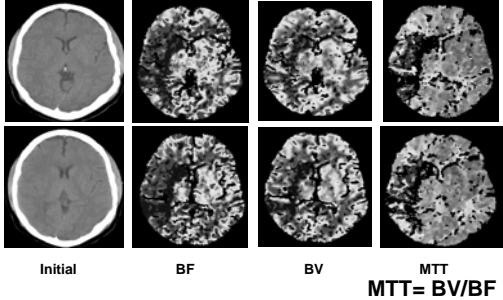
- International single-arm trial on a new generation device
- Allows for IV t-PA pretreatment
- Basilar, ICA-T, & M 1,2 occlusions
- 0-8 hours of symptom onset
- Outcomes
 - Recanalization (TIMI II/III)
 - Safety
- 163 patients enrolled



Returning to our Acute Stroke Case

- 50 yo male
- Awake, alert, dysarthric
- Fixed right sided gaze
- Left sided weakness
- CT less than 2 hours within symptom onset

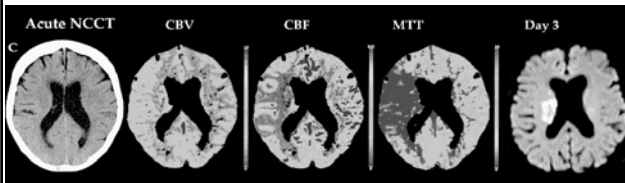
Acute Stroke Case: CTP



Changes in Cerebral Vascular Physiology with Worsening Circulatory Impairment

	CBF	CBV	MTT
Salvageable Penumbra	↓	↔↑	↑
Irretrievable Infarct	↓↓	↓	↑
	↓	↓	↑↑

Core Infarct and Penumbra



Parsons MW et al. *Neurology* 2007;68(10):730-6.

Are CTP Techniques Ready for Routine Use?

- CTP more accurate than unenhanced CT for detecting stroke and determining the extent of stroke
- Possible to distinguish penumbra from infarcted tissue
- Correlation between PCT/CTA and MRI is excellent
- Already used in DIAS and DEDAS

Wintermark M et al. *Am J Neuroradiol* 2005;26(1):104-12.
Wintermark M et al. *Stroke* 2006;37:979-985.
Wintermark M et al. *Neurology* 2007;68(9):694-697.

Conclusions

- Additional data are needed to identify which stroke patients should be selected for IA versus IV treatment
- Ongoing trials will identify if enhancement of IV tPA with ultrasound and/or other treatment modalities is efficacious
- Advanced neuroimaging techniques will make symptom onset time increasingly obsolete

ferne_memc_2007_NEtrack_asimos_stroke_100407