


**FERNE / MEMC IV Brain Illness and Injury Course:  
Lumbar Puncture Interpretation  
Heather Prendergast, MD, MPH, FACEP**

**Lumbar Puncture:  
Indications &  
Interpretation**

Heather Prendergast, MD, FACEP



**FERNE Brain Illness  
and Injury Course**

Heather Prendergast, MD, FACEP



The Fourth  
Mediterranean Brain and Injury Course (MEMC IV)  
Sorrento, Italy  
TE-19 Sorrento 2007



**4<sup>th</sup> Mediterranean  
Emergency Medicine  
Congress  
Sorrento, Italy  
September 17, 2007**

Heather Prendergast, MD, FACEP




**Heather M. Prendergast, MD,  
MPH, FACEP**

*Associate Professor*

*Department of Emergency Medicine  
University of Illinois College of Medicine  
Chicago, IL*

Heather Prendergast, MD, FACEP



**Disclosures**

- None


Heather Prendergast, MD, FACEP




**Session Objectives**

- Present a relevant patient case
- Discuss the indications and contraindications for lumbar puncture (LP)
- Differentiating between traumatic tap and a subarachnoid hemorrhage
- Review typical LP results for infectious processes

Heather Prendergast, MD, FACEP




## A Clinical Case

Heather Prendergast, MD, FACEP 


## ED Presentation

- 77 yo previously healthy female
- 3 day history of fever, confusion, and lethargy
- Glasgow Coma Scale 13 (E4,V4,M5)
- Key Aspects of Physical Exam:
  - Unable to cooperate with full neurological examination, +neck stiffness upon neck flexion

Heather Prendergast, MD, FACEP 

## Indications for Lumbar Puncture


- Diagnosis of central nervous system (CNS) infection
- Diagnosis of subarachnoid hemorrhage (SAH)
- Evaluation and diagnosis of demyelinating or inflammatory CNS processes
- Infusion of anesthetic, chemotherapy, or contrast agents into the spinal canal
- Treatment of idiopathic intracranial hypertension

Heather Prendergast, MD, FACEP 

## Indications for pre-LP head CT scan


**Table 2. Recommended criteria for adult patients with suspected bacterial meningitis who should undergo CT prior to lumbar puncture (B-II).**

Criterion	Comment
Immunocompromised state	HIV infection or AIDS, receiving immunosuppressive therapy, or after transplantation
History of CNS disease	Mass lesion, stroke, or focal infection
New onset seizure	Within 1 week of presentation, some authorities would not perform a lumbar puncture on patients with prolonged seizures or would delay lumbar puncture for 30 min in patients with short, convulsive seizures
Papilledema	Presence of venous pulsations suggests absence of increased intracranial pressure
Abnormal level of consciousness	...
Focal neurologic deficit	Including dilated nonreactive pupil, abnormalities of ocular motility, abnormal visual fields, gaze palsy, arm or leg drift

Heather Prendergast, MD, FACEP 


## Contraindications

- Skin infection near site of LP
- Suspicion of increased intracranial pressure due to cerebral mass
- Uncorrected coagulopathy
- Acute spinal cord trauma

Heather M. Prendergast, MD, MPH 

## Cerebrospinal Fluid (CSF)


- CSF secretion and reabsorption balanced when CSF pressure < 150mm H2O

Heather Prendergast, MD, FACEP 

## Opening Pressure

- Normal: 60-200 mm H<sub>2</sub>O (obese patients up to 250mm H<sub>2</sub>O)
- Elevated: Suggest increased intracranial pressures (>250 mm H<sub>2</sub>O)
  - Mass lesion (neoplasm, hemorrhage, infection)
  - Overproduction of CSF
  - Defective Outflow Mechanics


Heather Prendergast, MD, FACEP



## CSF Composition

- Color
  - Clear and colorless
  - Turbid
    - 200 WBCs or 400 RBCs
  - Grossly Bloody
    - 6000 RBCs


Heather Prendergast, MD, FACEP



## CSF Composition

- Cells
  - Acellular ( up to 5 WBCs and 5 RBCs)
  - More than 3 polymorphonuclear leukocytes (PMNs) abnormal



Heather Prendergast, MD, FACEP



## CSF Pleocytosis

- CSF pleocytosis
  - 10 white blood cells/μL, corrected for CSF red blood cells using a ratio of 1 WBC per 500 RBCs

Heather M. Prendergast, MD, MPH




The Journal of the American Medical Association

## Clinical Prediction Rule for Identifying Children With Cerebrospinal Fluid Pleocytosis at Very Low Risk of Bacterial Meningitis

JAMA. 2007;297:52-60.


Heather M. Prendergast, MD, MPH



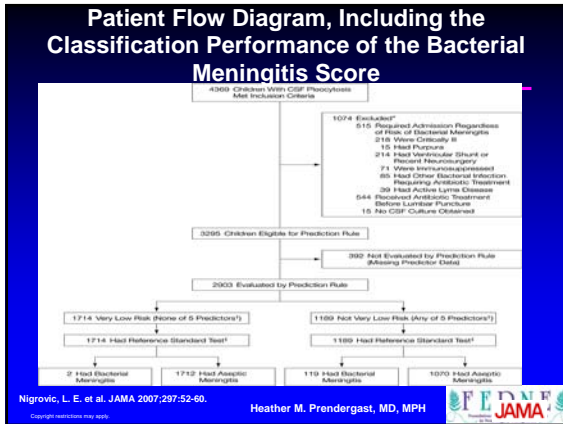
## CSF Pleocytosis & Bacterial Meningitis Score

- Criteria:
  - positive CSF Gram stain
  - CSF absolute neutrophil count (ANC) 1000 cells/μL
  - CSF protein 80 mg/dL
  - peripheral blood ANC>10,000/μL
  - history of seizure before or at presentation

Heather M. Prendergast, MD, MPH



**FERNE / MEMC IV Brain Illness and Injury Course:  
Lumbar Puncture Interpretation  
Heather Prendergast, MD, MPH, FACEP**



## Traumatic Tap

- Accidental trauma to a capillary or venule
- Increases both RBCs and WBCs in CSF
- If peripheral WBC normal subtract 1 WBC for every 500 RBC

## Xanthochromia

- Rapid lysis of RBC in the CSF
- Results of breakdown of hemoglobin
- Begins to appear 2-4 hours after RBCs enter subarachnoid space
- Persists for 2-4 weeks

## Calculating Predicted CSF WBC count

Predicted CSF WBC count/microL =

$$\text{CSF RBC count} \times (\text{peripheral blood WBC count} \div \text{peripheral RBC count})$$

## Validation of Prediction Calculation in Adults

- 720 patients
  - CSF WBC count >10X predicted value
    - Positive Predictive Value 48% for Bacterial Meningitis
  - CSF WBC count < 10X predicted value
    - Negative Predictive Value 99% for meningitis

## Validation of Prediction Calculation in Children

- 92 children
  - CSF WBC count >10X predicted value
    - 28/30 children (93%) bacterial meningitis
  - 57 children
    - CSF WBC count < 10X predicted
      - 100% for predicting the absence of meningitis

## CSF Composition

- Protein
  - Largely excluded from CSF by blood-CSF barrier
  - Normal range (adults) 23-38 mg/dL
  - False elevation
    - Diabetes, Presence of RBCS
  - True elevation
    - Infectious and Noninfectious Conditions
    - Persist for months in Meningitis

Heather M. Prendergast, MD, MPH



## CSF Composition

- Glucose
  - CSF-to-serum glucose ratio
    - Normal 0.6
  - Low CSF glucose concentrations
    - Bacterial meningitis
    - Mycobacterial and Fungal CNS infections
    - M. pneumoniae and Noninfectious processes
    - Less than 18 mg/dL strongly predictive of bacterial meningitis

Heather Prendergast, MD, FACEP



## CSF Composition

- Glucose
  - CSF-to-serum glucose ratio
    - Limited utility in Neonates, and severe hyperglycemia
  - Normal CSF glucose concentrations
    - Viral CNS infections
    - Exceptions:
      - mumps, enteroviruses, lymphocytic choriomeningitis(LCM), herpes simplex

Heather Prendergast, MD, FACEP



## CSF Composition

- Lactate
  - Elevated in bacterial meningitis
  - One study higher sensitivity and specificity than blood glucose ratio

Heather Prendergast, MD, FACEP



## CSF in CNS Infection

- Bacterial Meningitis
  - CSF WBC > 1000/microL ( with PMNs )
  - CSF Protein >250 mg/dL
  - CSF Glucose < 45 mg/dL (2.5 mmol/L)
  - CSF-blood glucose ratio  $\leq$  0.4 (LR 18)
  - CSF Lactate >31.53 mg/dL(3.5 mmol/L)

Heather Prendergast, MD, FACEP



## CSF in CNS Infection


- Viral Meningitis
  - CSF WBC < 250 / $\mu$ L (lymphocytes)
  - CSF Protein <150 mg/dL
  - CSF Glucose more than 50% of serum concentration


Heather Prendergast, MD, FACEP





### Summary of Typical CSF Findings

	Normal	Bacterial	Viral	TB
Cells	0-5	>1000	<1000	25-500
Polymorphs	0	Predominate	Early	+/- increased
Lymphocytes	5	Late	Predominate	Increased
Glucose	60-80	Decreased	Normal	Decreased
CSF plasma: Glucose ratio	66%	<40%	Normal	< 30%
Protein	5-40	Increased	+/- Increased	Increased
Culture	Negative	Positive	Negative	+TB

Heather Prendergast, MD, FACEP 

- ### Case Resolution
- CT scan: No mass lesion
  - CSF Results
    - WBC 5000 /µL
    - RBC 5 /microL
    - CSF blood glucose ratio 0.2
  - Gram stain: gram positive rods
- Heather Prendergast, MD, FACEP 

- ### Conclusions
- Primary indications for LP is to assess for meningitis or subarachnoid hemorrhage
  - Elevated opening pressures indicate increase intracranial pressures
  - Xanthochromia is always pathological
  - CSF is normally acellular
  - CSF Pleocytosis does not diagnosis infection
- Heather Prendergast, MD, FACEP 

- ### Recommendations
- Calculate CSF-blood glucose ratio.
    - 0.4 or less (LR 18) bacterial meningitis
  - Determine the predicted CSF WBC count
    - Negative Predictive Value 99% for bacterial meningitis
  - Utilize the Bacterial Meningitis score in cases of CSF Pleocytosis
- Heather Prendergast, MD, FACEP 

## Questions?

[www.FERNE.org](http://www.FERNE.org)

[hprender@uic.edu](mailto:hprender@uic.edu)

312 413 1214

ferne\_memc\_2007\_braincourse\_prendergast\_lp\_interpretation\_091707\_finalcd  
9/27/2007 9:11 AM Heather Prendergast, MD, FACEP 