


**FERNE / MEMC IV Brain Illness and Injury Course:
Lumbar Puncture
Heather Prendergast, MD, MPH, FACEP**

**Lumbar Puncture:
Indications and
Procedure**

Heather Prendergast, MD, FACEP



**FERNE Brain Illness
and Injury Course**

Heather Prendergast, MD, FACEP



The Fourth
Mediterranean Brain and Injury Course (MEMC IV)
Sorrento, Italy
September 17, 2007



**4th Mediterranean
Emergency Medicine
Congress
Sorrento, Italy
September 17, 2007**

Heather Prendergast, MD, FACEP



**Heather M. Prendergast, MD,
MPH, FACEP**

Associate Professor

*Department of Emergency Medicine
University of Illinois College of Medicine
Chicago, IL*

Heather Prendergast, MD, FACEP



Disclosures

- None


Heather Prendergast, MD, FACEP



Session Objectives

- Present a relevant patient case
- Discuss the indications and contraindications for lumbar puncture (LP)
- Review the procedure of LP
- Present techniques to minimize post LP headache
- State the indications for opening pressure determination and interpretation of measurements

Heather Prendergast, MD, FACEP



A Clinical Case


Heather Prendergast, MD, FACEP



ED Presentation

- 77 yo previously healthy female
- 3 day history of confusion, and lethargy
- Glasgow Coma Scale 13 (E4,V4,M5)
- Key Aspects of Physical Exam:
 - Unable to cooperate with full physical examination, +neck stiffness upon neck flexion


Heather Prendergast, MD, FACEP



ED Course

- Basic Labs
 - CBC, Electrolytes normal
 - Urinalysis: normal
 - Chest radiograph: normal

Heather Prendergast, MD, FACEP




Why Consider This Case?

The Journal of Emergency Medicine
Official Journal of American Academy of Emergency Medicine

Utility of lumbar puncture in the afebrile vs. febrile elderly patient with altered mental status: a pilot study

Kaushal Shah MD¹, Kathleen Richard² and Jonathan A. Edlow MD³
¹Dartmouth Medical School, Hanover, New Hampshire
²Department of Emergency Medicine, Beth Israel Deaconess Medical Center, Boston, Massachusetts
³Department of Emergency Medicine, St. Luke's-Roosevelt Hospital, New York, New York


Heather Prendergast, MD, FACEP



Lumbar Puncture

- Diagnostic Test for infectious and noninfectious neurologic conditions
- Rarely diagnostic as a single agent
- Combine with history, physical and selected lab tests


Heather Prendergast, MD, FACEP



Indications for Lumbar Puncture

- Diagnosis of central nervous system (CNS) infection
- Diagnosis of subarachnoid hemorrhage (SAH)
- Evaluation and diagnosis of demyelinating or inflammatory CNS processes
- Infusion of anesthetic, chemotherapy, or contrast agents into the spinal canal
- Treatment of idiopathic intracranial hypertension

Heather Prendergast, MD, FACEP




**FERNE / MEMC IV Brain Illness and Injury Course:
Lumbar Puncture
Heather Prendergast, MD, MPH, FACEP**

Indications for pre-LP head CT scan

Table 2. Recommended criteria for adult patients with suspected bacterial meningitis who should undergo CT prior to lumbar puncture (B-II).


Criterion	Comment
Immunocompromised state	HIV infection or AIDS, receiving immunosuppressive therapy, or after transplantation
History of CNS disease	Mass lesion, stroke, or focal infection
New onset seizure	Within 1 week of presentation, some authorities would not perform a lumbar puncture on patients with prolonged seizures or would delay lumbar puncture for 30 min in patients with short, convulsive seizures
Papilledema	Presence of venous pulsations suggests absence of increased intracranial pressure
Abnormal level of consciousness	...
Focal neurologic deficit	Including dilated nonreactive pupil, abnormalities of ocular motility, abnormal visual fields, gaze palsy, arm or leg drift


Heather Prendergast, MD, FACEP 

Indications for pre-LP head CT scan

Table 2. Recommended criteria for adult patients with suspected bacterial meningitis who should undergo CT prior to lumbar puncture (B-II).


Criterion	Comment
Immunocompromised state	HIV infection or AIDS, receiving immunosuppressive therapy, or after transplantation
History of CNS disease	Mass lesion, stroke, or focal infection
New onset seizure	Within 1 week of presentation, some authorities would not perform a lumbar puncture on patients with prolonged seizures or would delay lumbar puncture for 30 min in patients with short, convulsive seizures
Papilledema	Presence of venous pulsations suggests absence of increased intracranial pressure
Abnormal level of consciousness	...
Focal neurologic deficit	Including dilated nonreactive pupil, abnormalities of ocular motility, abnormal visual fields, gaze palsy, arm or leg drift

Heather Prendergast, MD, FACEP 




Contraindications

- Skin infection near site of LP
- Suspicion of intracranial pressure due to cerebral mass
- Uncorrected coagulopathy
- Acute spinal cord trauma

Heather M. Prendergast, MD, MPH 


Technique

- Lateral Recumbent position
- Sitting upright

Heather Prendergast, MD, FACEP 

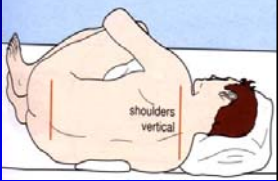
Procedure

- Determine correct level of entry
- Highest points of the iliac crests should be identified and palpated
- Direct line joining the crests identifies L4
- Spinous processes L3, L4, and L5 can be directly palpated
- Goal: Subarachnoid space at L3/4 or L4/5


Heather Prendergast, MD, FACEP 

Positioning: Key to Success


- Fetal position with neck, back, and limbs held in flexion
- Lower lumbar spine flexed with back *perfectly* perpendicular to edge of bed
- Hips and legs should be parallel to each other and perpendicular to table



Heather Prendergast, MD, FACEP




Positioning




INCORRECT CORRECT

Heather Prendergast, MD, FACEP




Skin Preparation

- Overlying skin cleaned with povidone-iodine
- Sterile drape placed with an opening over the LS

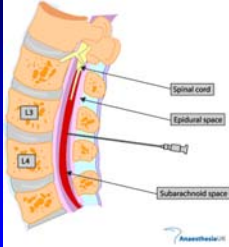


Heather Prendergast, MD, FACEP




Spinal Needle Insertion

- Local anesthesia infiltrated
- 20 or 22 gauge spinal needle with stylet
- Advance spinal needle slowly, angling slightly toward the head
- Flat surface of bevel of needle positioned to face patient's flanks




Heather M. Prendergast, MD, MPH



Post-LP Headache

- Etiology: Prolonged leakage of cerebrospinal fluid due to delayed closure of dural defect
 - Low CSF pressure
 - Incidence 1-70%
 - Contributing factors
 - Diameter of needle, shape of needle, diagnostic vs. spinal anesthesia


Heather M. Prendergast, MD, MPH



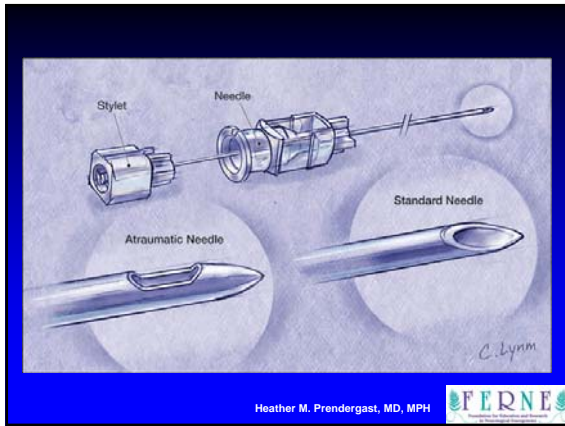
Minimizing Post-LP Headache

- Techniques:
 - Needle choice
 - Standard Quincke vs. Atraumatic
 - Number of attempts
 - Reinsertion of Stylet
 - Bed Rest after Procedure

Heather M. Prendergast, MD, MPH



**FERNE / MEMC IV Brain Illness and Injury Course:
Lumbar Puncture
Heather Prendergast, MD, MPH, FACEP**




Heather M. Prendergast, MD, MPH

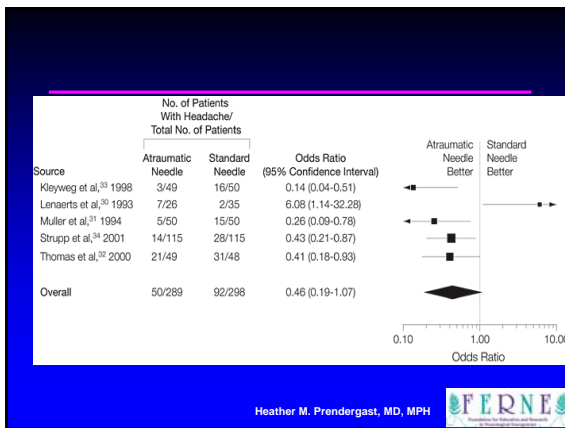


Post LP Headache

- **Quincke:**
 - Reduction in post LP headache as great as 50%
- **“Atraumatic”**
 - Post LP headache rates of 2-6%



Heather M. Prendergast, MD, MPH



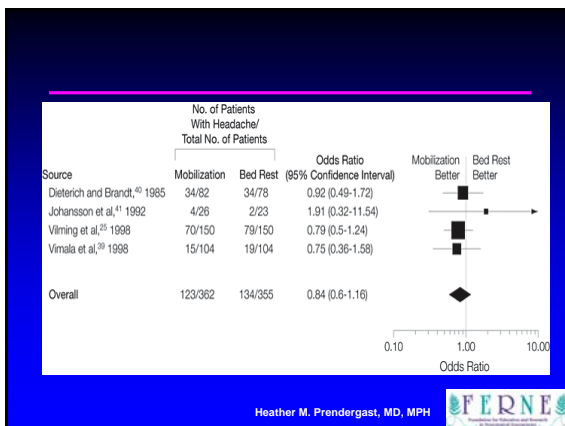
Heather M. Prendergast, MD, MPH



Reinsertion of Stylet

- **600 patients**
 - Post lumbar puncture syndrome
 - 49/300 (16 %) no reinsertion
 - 15/300 (5%) reinsertion

Heather M. Prendergast, MD, MPH

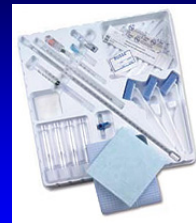

Heather M. Prendergast, MD, MPH



Measuring Opening Pressure

- Once CSF appears attach manometer through stopcock
- Note the height of the fluid column
- Have patient straighten legs to avoid falsely elevated pressure



Heather M. Prendergast, MD, MPH



**FERNE / MEMC IV Brain Illness and Injury Course:
Lumbar Puncture
Heather Prendergast, MD, MPH, FACEP**

Understanding Opening Pressures

- **Normal: 60-200 mm H₂O (obese patients up to 250mm H₂O)**
- **Elevated: Suggest increased intracranial pressures (>250 mm H₂O)**
 - Mass lesion (neoplasm, hemorrhage, infection)
 - Overproduction of CSF
 - Defective Outflow Mechanics

Heather M. Prendergast, MD, MPH



Case Resolution

- Fever, confusion, and Neck stiffness
- Head CT indicated PRIOR to LP
 - Unable to complete full neurological exam
 - Altered mental status
 - Inability to confirm absence of focal neurological deficit

Heather Prendergast, MD, FACEP



Conclusions

- ED seizure patient Rx needs to address both the immediate seizure and the long-term epilepsy management
- In general, ED seizure patient Rx focuses on parenteral AED use
- Oral Rx, 2nd generation AEDs useful
- Must understand principles that govern ED AED use and priorities of those that provide long-term epilepsy Rx

Heather Prendergast, MD, FACEP



Recommendations

- Be able to identify the seizure type and optimal patient therapies based on etiology, demographics, and risk/benefit
- Establish seizure and SE protocol
- Understand fully the optimal use of parenteral and 2nd generation AEDs
- Stop the acute seizure & prevent SE
- Wisely prescribe so that follow-up epilepsy management can be optimized

Heather Prendergast, MD, FACEP



Lumbar Puncture: Indications & Interpretation

Heather Prendergast, MD, FACEP



FERNE Brain Illness and Injury Course

Heather Prendergast, MD, FACEP



**FERNE / MEMC IV Brain Illness and Injury Course:
Lumbar Puncture
Heather Prendergast, MD, MPH, FACEP**

The Forum
Mediterranean Emergency Medicine Congress (MEMC IV)
Sorrento, Italy
15-19 September 2007

**4th Mediterranean
Emergency Medicine
Congress
Sorrento, Italy
September 17, 2007**

Heather Prendergast, MD, FACEP

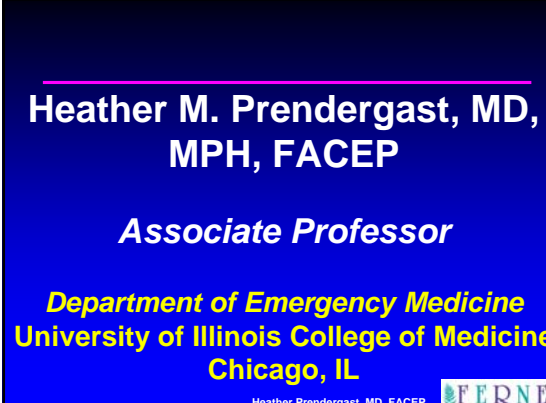


**Heather M. Prendergast, MD,
MPH, FACEP**

Associate Professor

*Department of Emergency Medicine
University of Illinois College of Medicine
Chicago, IL*

Heather Prendergast, MD, FACEP



Disclosures

- None

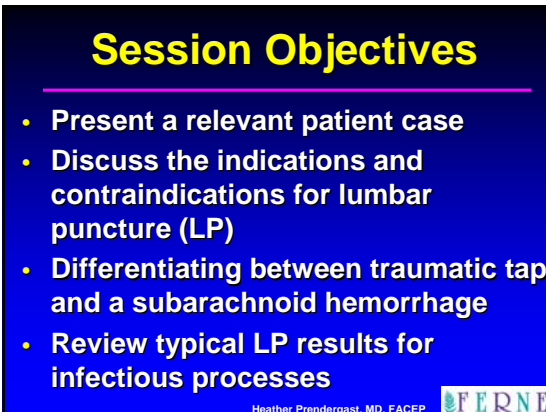
Heather Prendergast, MD, FACEP



Session Objectives

- Present a relevant patient case
- Discuss the indications and contraindications for lumbar puncture (LP)
- Differentiating between traumatic tap and a subarachnoid hemorrhage
- Review typical LP results for infectious processes

Heather Prendergast, MD, FACEP



A Clinical Case

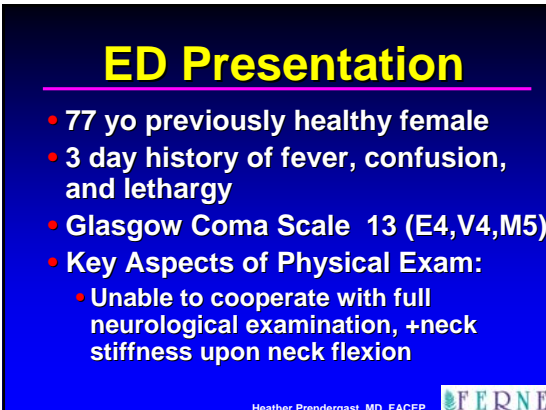
Heather Prendergast, MD, FACEP



ED Presentation

- 77 yo previously healthy female
- 3 day history of fever, confusion, and lethargy
- Glasgow Coma Scale 13 (E4,V4,M5)
- Key Aspects of Physical Exam:
 - Unable to cooperate with full neurological examination, +neck stiffness upon neck flexion

Heather Prendergast, MD, FACEP



Indications for Lumbar Puncture

- **Diagnosis of central nervous system (CNS) infection**
- **Diagnosis of subarachnoid hemorrhage (SAH)**
- **Evaluation and diagnosis of demyelinating or inflammatory CNS processes**
- **Infusion of anesthetic, chemotherapy, or contrast agents into the spinal canal**
- **Treatment of idiopathic intracranial hypertension**

Heather Prendergast, MD, FACEP



Indications for pre-LP head CT scan

Table 2. Recommended criteria for adult patients with suspected bacterial meningitis who should undergo CT prior to lumbar puncture (B-II).

Criterion	Comment
Immunocompromised state	HIV infection or AIDS, receiving immunosuppressive therapy, or after transplantation
History of CNS disease	Mass lesion, stroke, or focal infection
New onset seizure	Within 1 week of presentation, some authorities would not perform a lumbar puncture on patients with prolonged seizures or would delay lumbar puncture for 30 min in patients with short, convulsive seizures
Papilledema	Presence of venous pulsations suggests absence of increased intracranial pressure
Abnormal level of consciousness	---
Focal neurologic deficit	Including dilated nonreactive pupil, abnormalities of ocular motility, abnormal visual fields, gaze palsy, arm or leg drift

Heather Prendergast, MD, FACEP



Contraindications

- **Skin infection near site of LP**
- **Suspicion of increased intracranial pressure due to cerebral mass**
- **Uncorrected coagulopathy**
- **Acute spinal cord trauma**

Heather Prendergast, MD, FACEP



Cerebrospinal Fluid (CSF)

- **CSF secretion and reabsorption balanced when CSF pressure < 150mm H₂O**

Heather Prendergast, MD, FACEP



Opening Pressure

- **Normal: 60-200 mm H₂O (obese patients up to 250mm H₂O)**
- **Elevated: Suggest increased intracranial pressures (>250 mm H₂O)**
 - Mass lesion (neoplasm, hemorrhage, infection)
 - Overproduction of CSF
 - Defective Outflow Mechanics

Heather Prendergast, MD, FACEP



CSF Composition


- **Color**
 - Clear and colorless
 - Turbid
 - 200 WBCs or 400 RBCs
 - Grossly Bloody
 - 6000 RBCs

Heather Prendergast, MD, FACEP




CSF Composition


- **Cells**
 - Acellular (up to 5 WBCs and 5 RBCs)
 - More than 3 polymorphonuclear leuckocytes (PMNs) abnormal

Heather Prendergast, MD, FACEP 

CSF Pleocytosis


- **CSF pleocytosis**
 - 10 white blood cells/ μ L, corrected for CSF red blood cells using a ratio of 1 WBC per 500 RBCs

Heather Prendergast, MD, FACEP 




Clinical Prediction Rule for Identifying Children With Cerebrospinal Fluid Pleocytosis at Very Low Risk of Bacterial Meningitis

JAMA. 2007;297:52-60.


Heather Prendergast, MD, FACEP 

CSF Pleocytosis & Bacterial Meningitis Score


- **Criteria:**
 - positive CSF Gram stain
 - CSF absolute neutrophil count (ANC) 1000 cells/ μ L
 - CSF protein 80 mg/dL
 - peripheral blood ANC > 10,000/ μ L
 - history of seizure before or at presentation

Heather Prendergast, MD, FACEP 

Patient Flow Diagram, Including the Classification Performance of the Bacterial Meningitis Score




Nigrovic, L. E. et al. JAMA 2007;297:52-60. Copyright restrictions may apply.

Heather Prendergast, MD, FACEP 

Traumatic Tap

- Accidental trauma to a capillary or venule
- Increases both RBCs and WBCs in CSF
- If peripheral WBC normal subtract 1 WBC for every 500 RBC

Heather Prendergast, MD, FACEP 

Xanthochromia

- Rapid lysis of RBC in the CSF
- Results of breakdown of hemoglobin
- Begins to appear 2-4 hours after RBCs enter subarachnoid space
- Persists for 2-4 weeks

Heather Prendergast, MD, FACEP



Calculating Predicted CSF WBC count

Predicted CSF WBC count/microL =

CSF RBC count X (peripheral blood WBC count ÷ peripheral RBC count)

Heather Prendergast, MD, FACEP



Validation of Prediction Calculation in Adults

- 720 patients
 - CSF WBC count >10X predicted value
 - Positive Predictive Value 48% for Bacterial Meningitis
 - CSF WBC count < 10X predicted value
 - Negative Predictive Value 99% for meningitis

Heather Prendergast, MD, FACEP



Validation of Prediction Calculation in Children

- 92 children
 - CSF WBC count >10X predicted value
 - 28/30 children (93%) bacterial meningitis
- 57 children
 - CSF WBC count < 10X predicted
 - 100% for predicting the absence of meningitis

Heather Prendergast, MD, FACEP



CSF Composition

- Protein
 - Largely excluded from CSF by blood-CSF barrier
 - Normal range (adults) 23-38 mg/dL
 - False elevation
 - Diabetes, Presence of RBCS
 - True elevation
 - Infectious and Noninfectious Conditions
 - Persist for months in Meningitis

Heather Prendergast, MD, FACEP



CSF Composition


- Glucose
 - CSF-to-serum glucose ratio
 - Normal 0.6
 - Low CSF glucose concentrations
 - Bacterial meningitis
 - Mycobacterial and Fungal CNS infections
 - M. pneumoniae and Noninfectious processes
 - Less than 18 mg/dL strongly predictive of bacterial meningitis

Heather Prendergast, MD, FACEP




CSF Composition

- **Glucose**
 - CSF-to-serum glucose ratio
 - Limited utility in Neonates, and severe hyperglycemia
 - Normal CSF glucose concentrations
 - Viral CNS infections
 - Exceptions:
 - mumps, enteroviruses, lymphocytic choriomeningitis(LCM), herpes simplex

Heather Prendergast, MD, FACEP 


CSF Composition

- **Lactate**
 - Elevated in bacterial meningitis
 - One study higher sensitivity and specificity than blood glucose ratio

Heather Prendergast, MD, FACEP 


CSF in CNS Infection

- **Bacterial Meningitis**
 - CSF WBC > 1000/microL (with PMNs)
 - CSF Protein >250 mg/dL
 - CSF Glucose < 45 mg/dL (2.5 mmol/L)
 - CSF-blood glucose ratio \leq 0.4 (LR 18)
 - CSF Lactate >31.53 mg/dL(3.5 mmol/L)

Heather Prendergast, MD, FACEP 


CSF in CNS Infection

- **Viral Meningitis**
 - CSF WBC < 250 / μ L (lymphocytes)
 - CSF Protein <150 mg/dL
 - CSF Glucose more than 50% of serum concentration

Heather Prendergast, MD, FACEP 


Summary of Typical CSF Findings

	Normal	Bacterial	Viral	TB
Cells	0-5	>1000	<1000	25-500
Polymorphs	0	Predominate	Early	+/- increased
Lymphocytes	5	Late	Predominate	Increased
Glucose	60-80	Decreased	Normal	Decreased
CSF plasma: Glucose ratio	66%	<40%	Normal	< 30%
Protein	5-40	Increased	+/- Increased	Increased
Culture	Negative	Positive	Negative	+TB

Heather Prendergast, MD, FACEP 

Case Resolution

- **CT scan: No mass lesion**
- **CSF Results**
 - WBC 5000 / μ L
 - RBC 5 /microL
 - CSF blood glucose ratio 0.2
- **Gram stain: gram positive rods**

Heather Prendergast, MD, FACEP 

**FERNE / MEMC IV Brain Illness and Injury Course:
Lumbar Puncture
Heather Prendergast, MD, MPH, FACEP**

Conclusions

- Primary indications for LP is to assess for meningitis or subarachnoid hemorrhage
- Elevated opening pressures indicate increase intracranial pressures
- Xanthochromia is always pathological
- CSF is normally acellular
- CSF Pleocytosis does not diagnosis infection

Heather Prendergast, MD, FACEP



Recommendations

- Calculate CSF-blood glucose ratio.
 - 0.4 or less (LR 18) bacterial meningitis
- Determine the predicted CSF WBC count
 - Negative Predictive Value 99% for bacterial meningitis
- Utilize the Bacterial Meningitis score in cases of CSF Pleocytosis

Heather Prendergast, MD, FACEP



Questions?

www.FERNE.org

hprender@uic.edu

312 413 1214

ferne_menc_2007_braincourse_prendergast_lumbar_puncture_092707_final01.ppt

9/27/2007 9:38 AM

Heather Prendergast, MD, FACEP

